


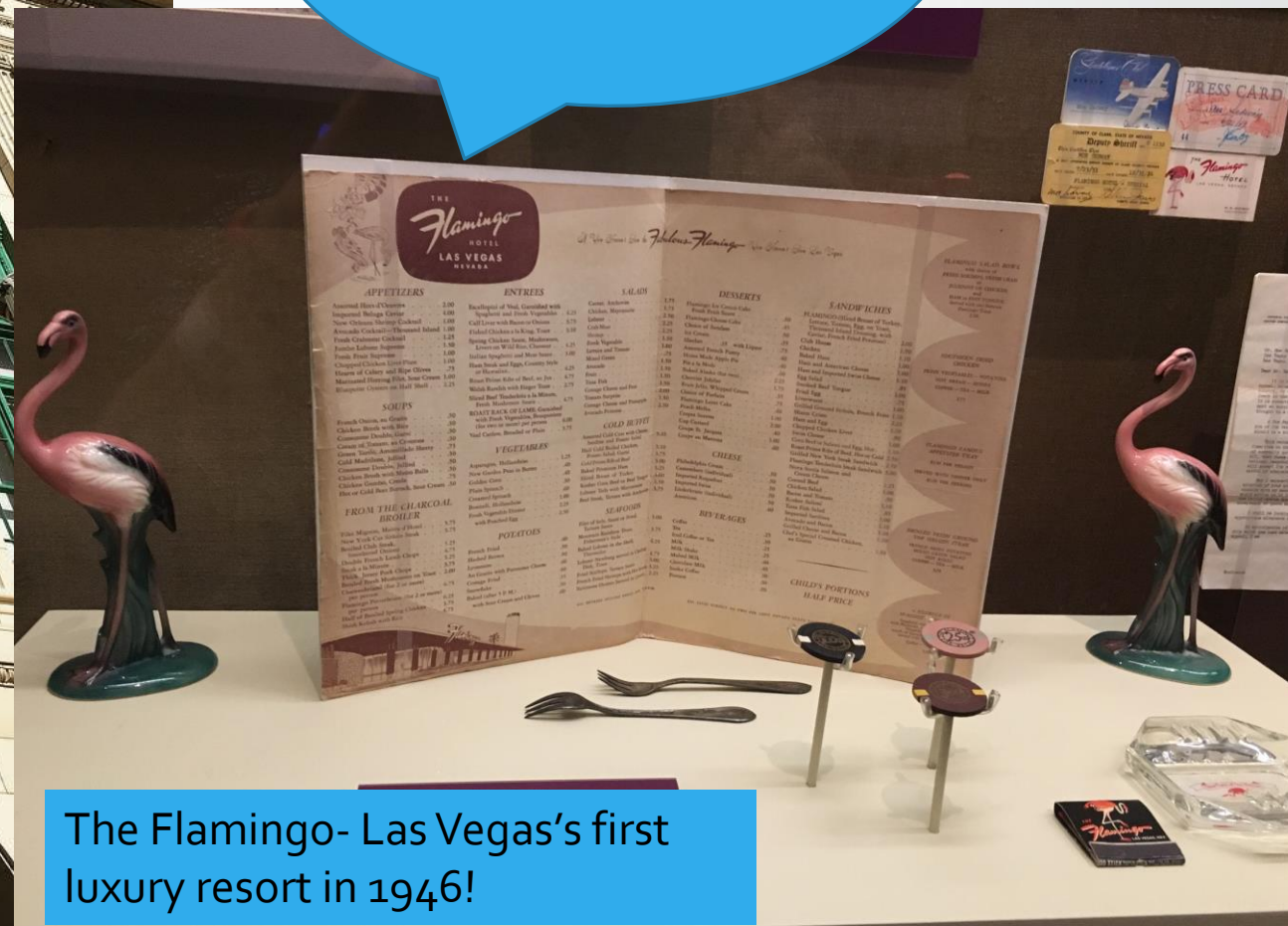
# Mastering Your Musculoskeletal Exam

Laurel Short, MSN, FNP-c



Filet Mignon...5.75  
Rack of Lamb...6.00



The Flamingo- Las Vegas's first luxury resort in 1946!

# Disclosure

- I have no current affiliation or financial interest with any grantor or commercial interests that may have direct interest in the subject matter of the CE Program.




# Here's what we'll cover

- Review key components of a comprehensive musculoskeletal exam
- Describe an organized approach to exam techniques
- Identify history questions used to assess patients presenting with problems for the upper and lower extremity
- Identify functional anatomy with clinical significant for the upper and lower limb

## MSK Exam and Primary Care

Musculoskeletal problems are in the top reasons for PCP visits

Over half of chronic medical conditions in the U.S. are related to MSK diagnoses



# Components of MSK Exam

- Observation
- Palpation
- Active & Passive range of motion (ROM)
- Strength
- Reflexes and Sensation
- Gait

# Helpful Terms

- Abduction
- Adduction
- Proximal
- Distal
- Origin
- Insertion
- Volar
- Dorsal
- Valgus
- Varus



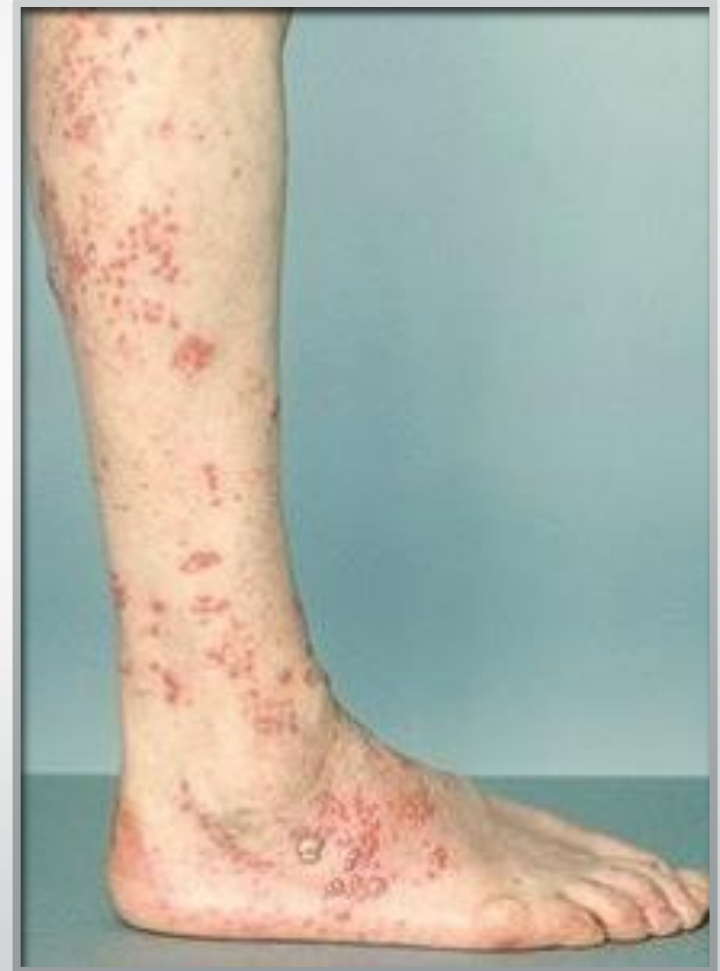

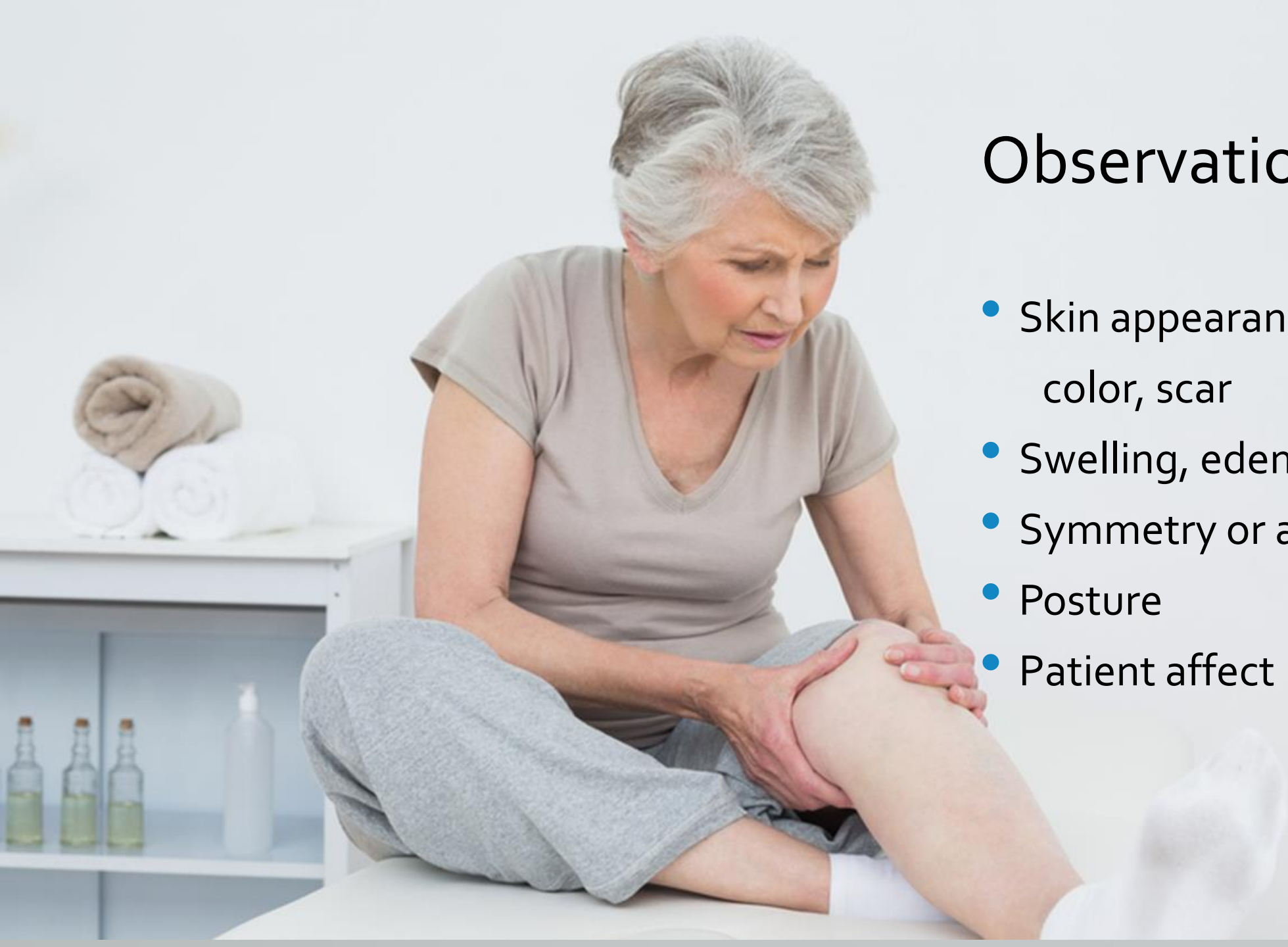Observation

## Observation

Patient's description in initial call to clinic:  
*Pain, burning, numbness, tingling.*

When he is seen for his appointment, he has developed this rash with blisters and itching:

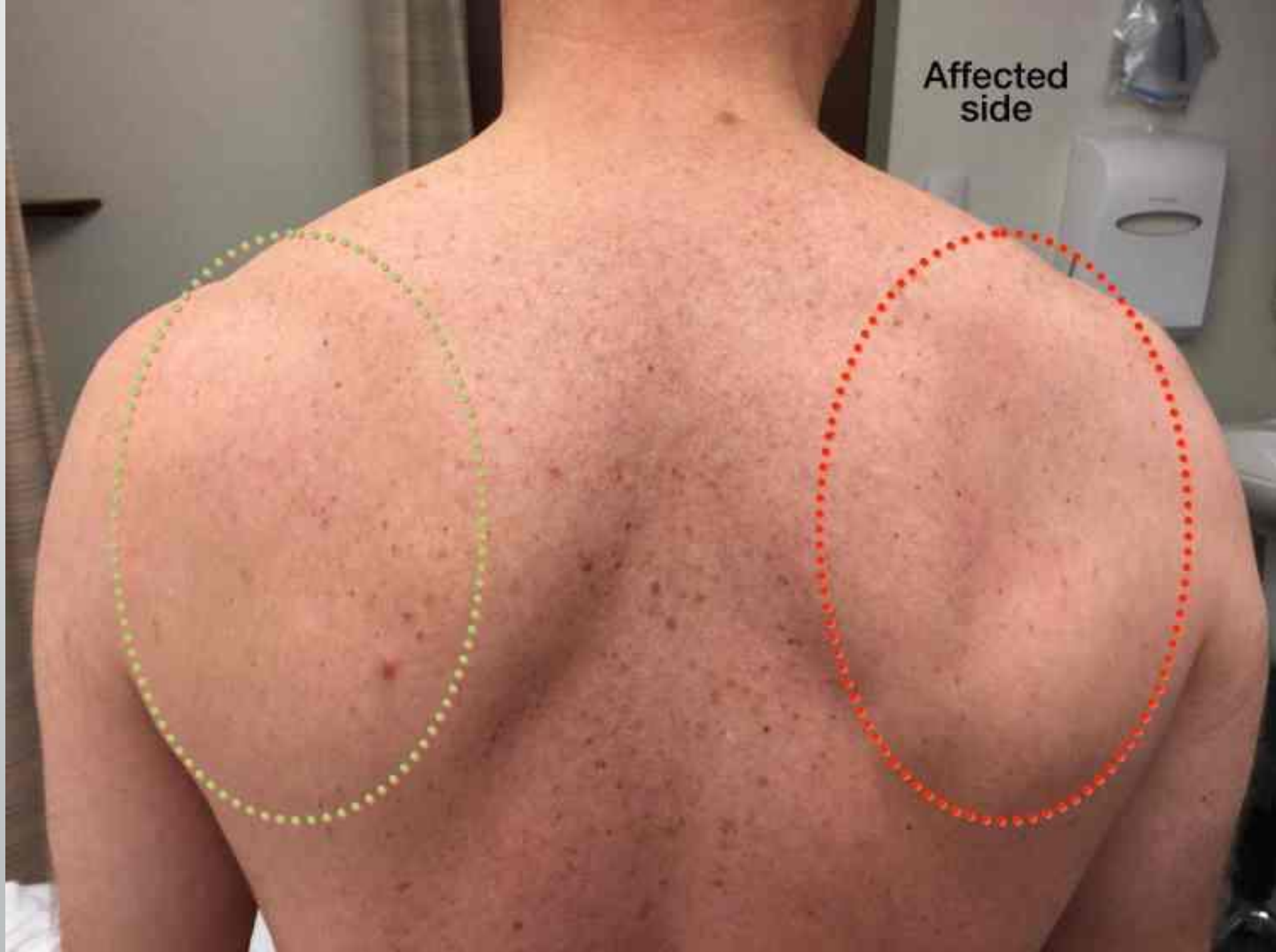


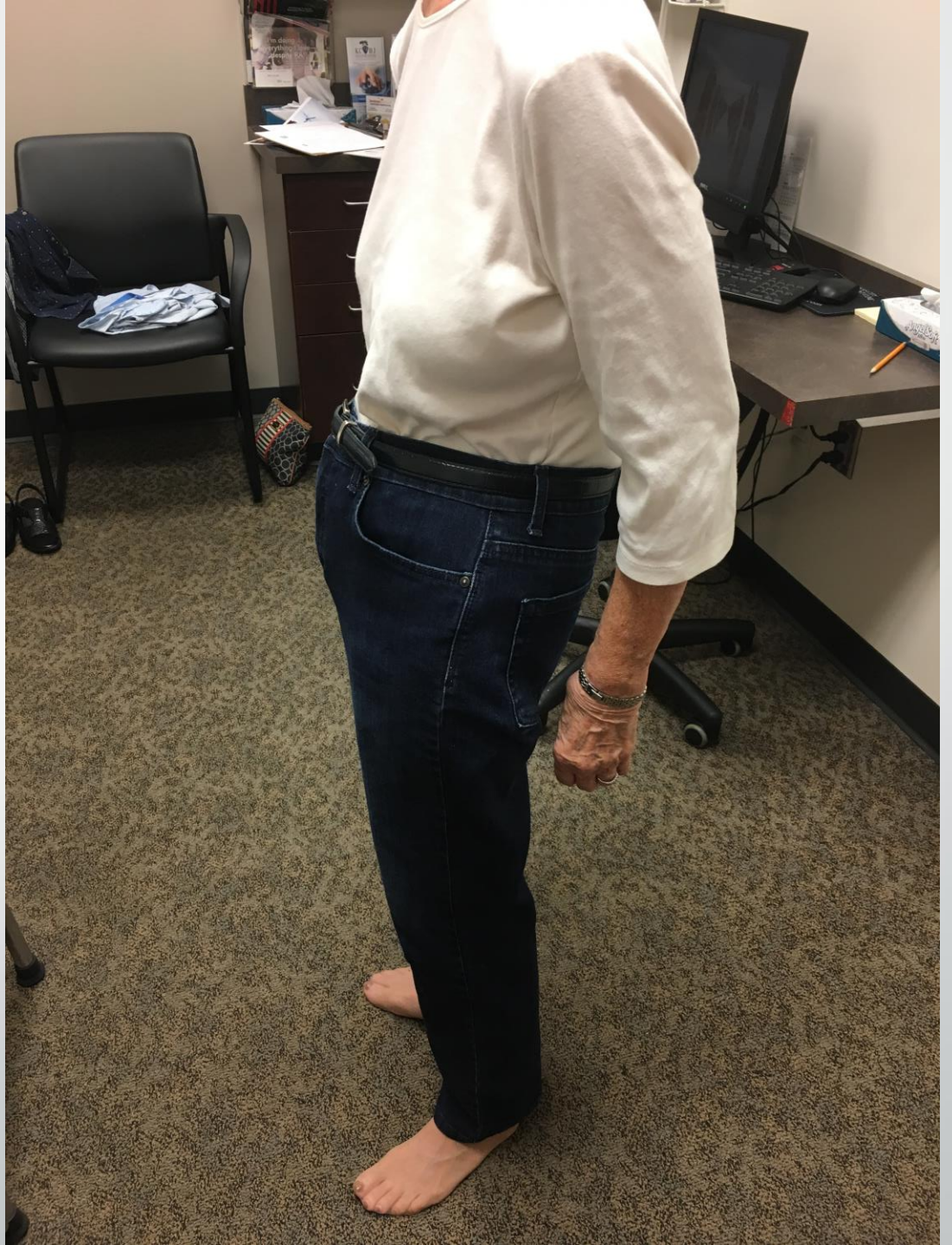
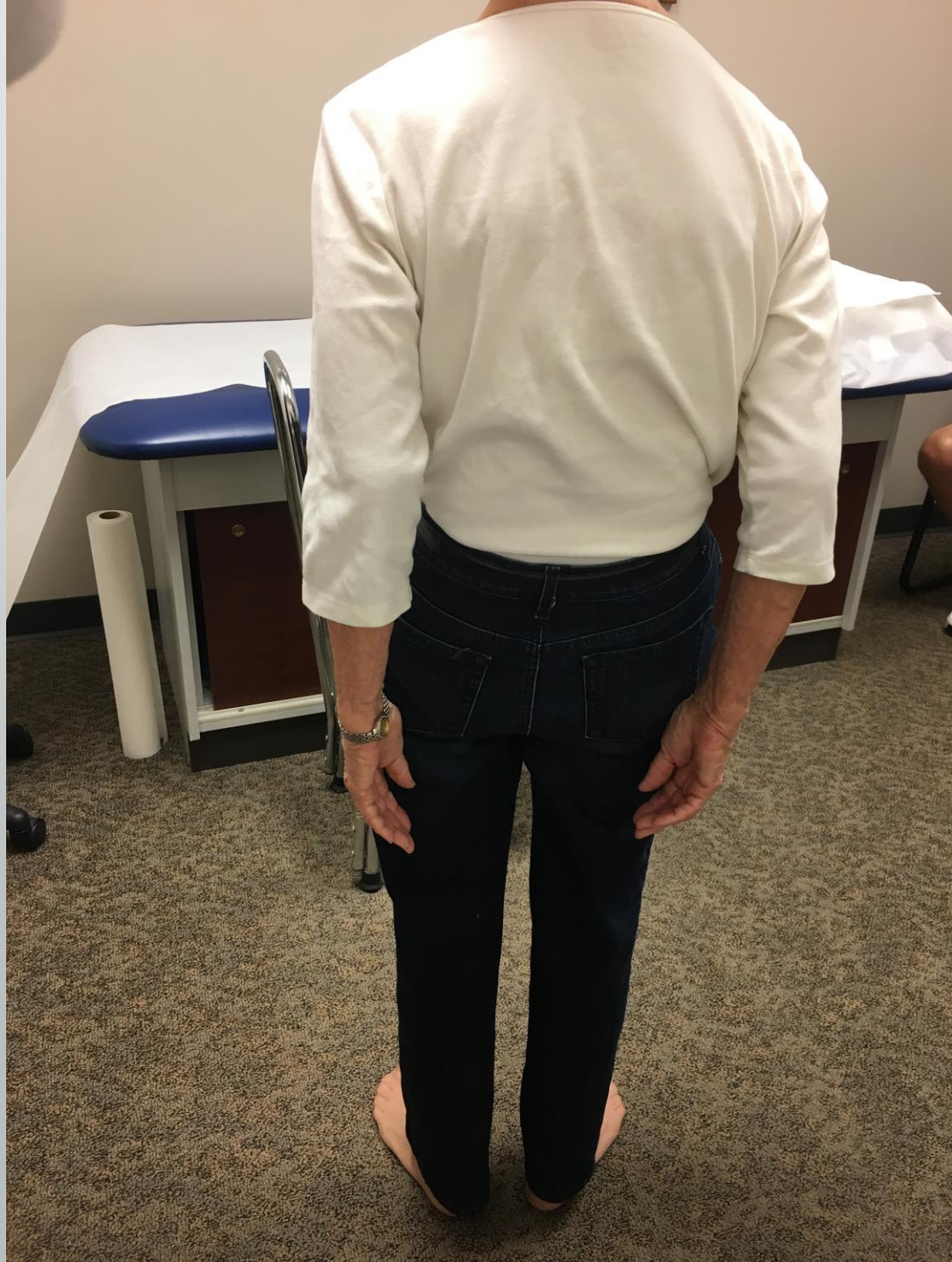
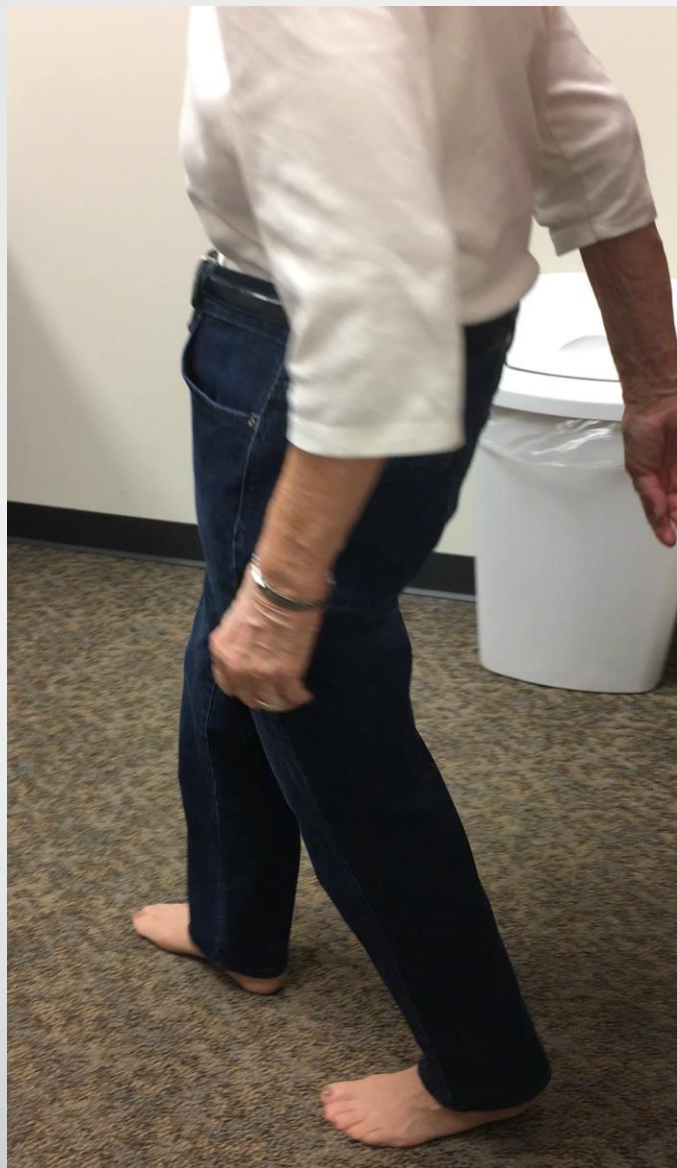# Observation

- Skin appearance- breakdown, color, scar
- Swelling, edema, erythema
- Symmetry or asymmetry
- Posture
- Patient affect

Affected side





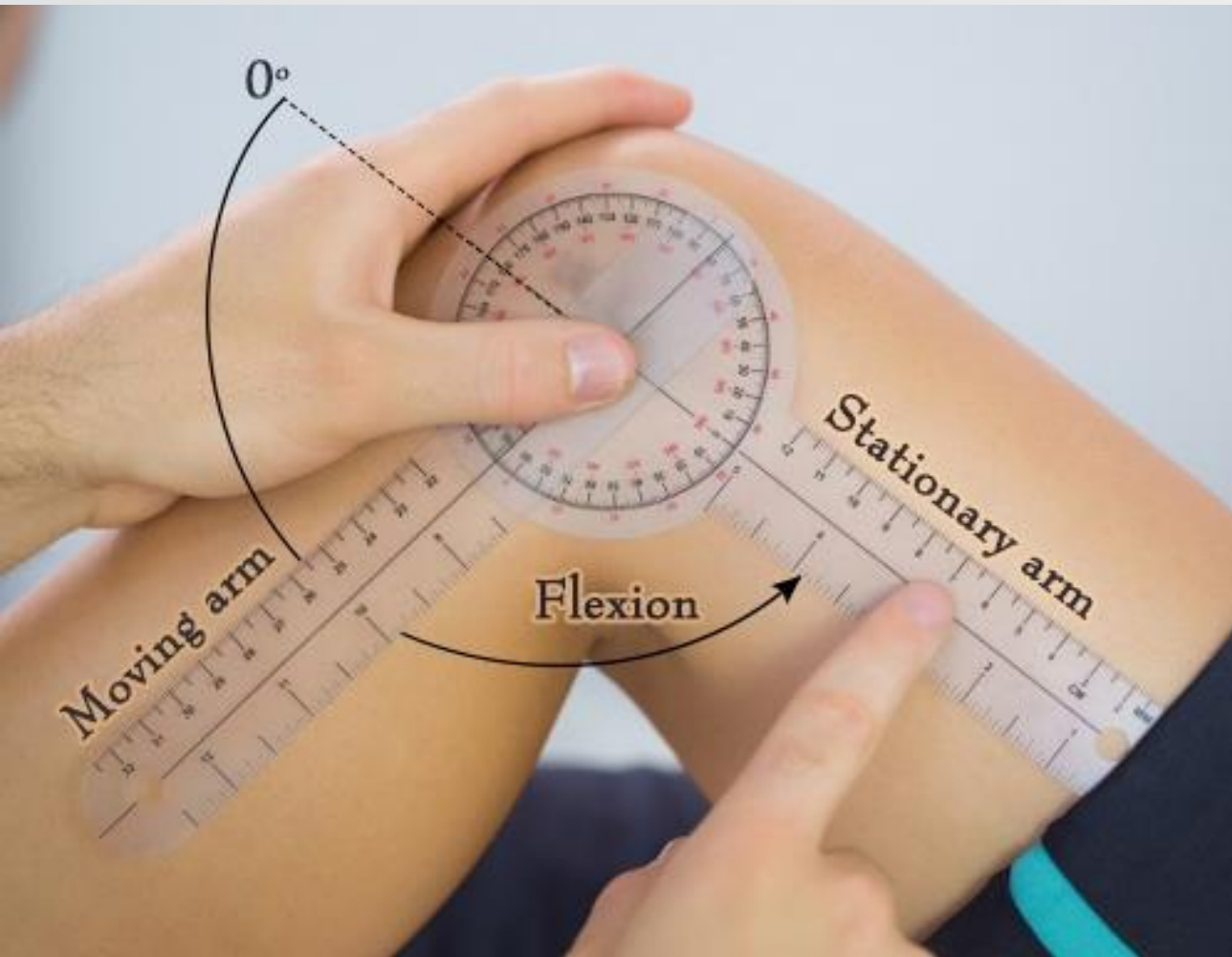


# Palpation

- Pressure level: light prior to firm
- Identify location: tendon attachment, muscle, joint?
- Type of pain provoked
- Focal vs. radiating pain







Range of Motion

# Range of Motion

- Passive vs. Active
- Types of joints
- Is range limited due to pain/guarding, weakness, or muscle/joint issue?
- Always check the unaffected side first for comparison
- Is there pain associated with the reduced range of motion?



# American Spinal Injury Association Strength Grading

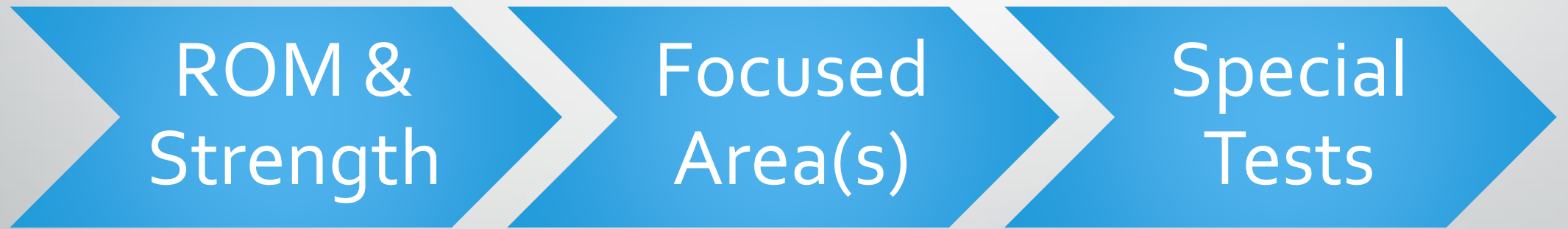
- 0 Total paralysis
- 1 Palpable or visible contraction
- 2 Active Movement
- 3 Active movement against gravity
- 4 Active movement against gravity with some degree of resistance
- 5 Active movement with full resistance (normal)

# Reflex Grading

- 0 No response
- 1+ Slight by definite response (may or may not be normal)
- 2+ Brisk response (normal)
- 3+ Very brisk (may or may not be normal)
- 4+ Repeating response/clonus (always abnormal)



# Approach to Exam



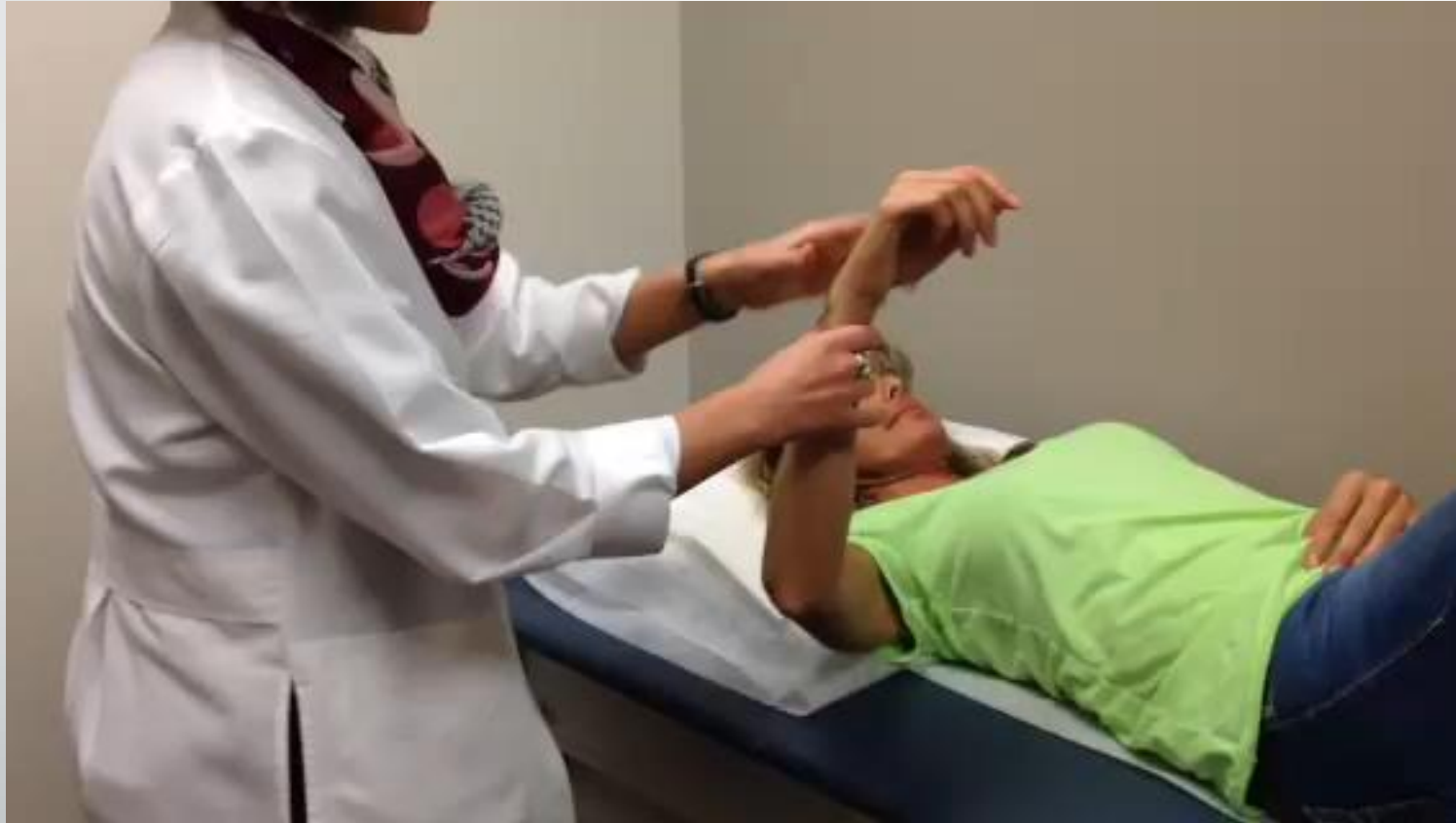

Upper Limb

# Shoulder

- Very mobile joint with shallow glenoid fossa
- Stability depends on muscles and connective tissue
- Assess posture!
- Special tests: Impingement, Drop Arm, Apprehension, Wall Push-up



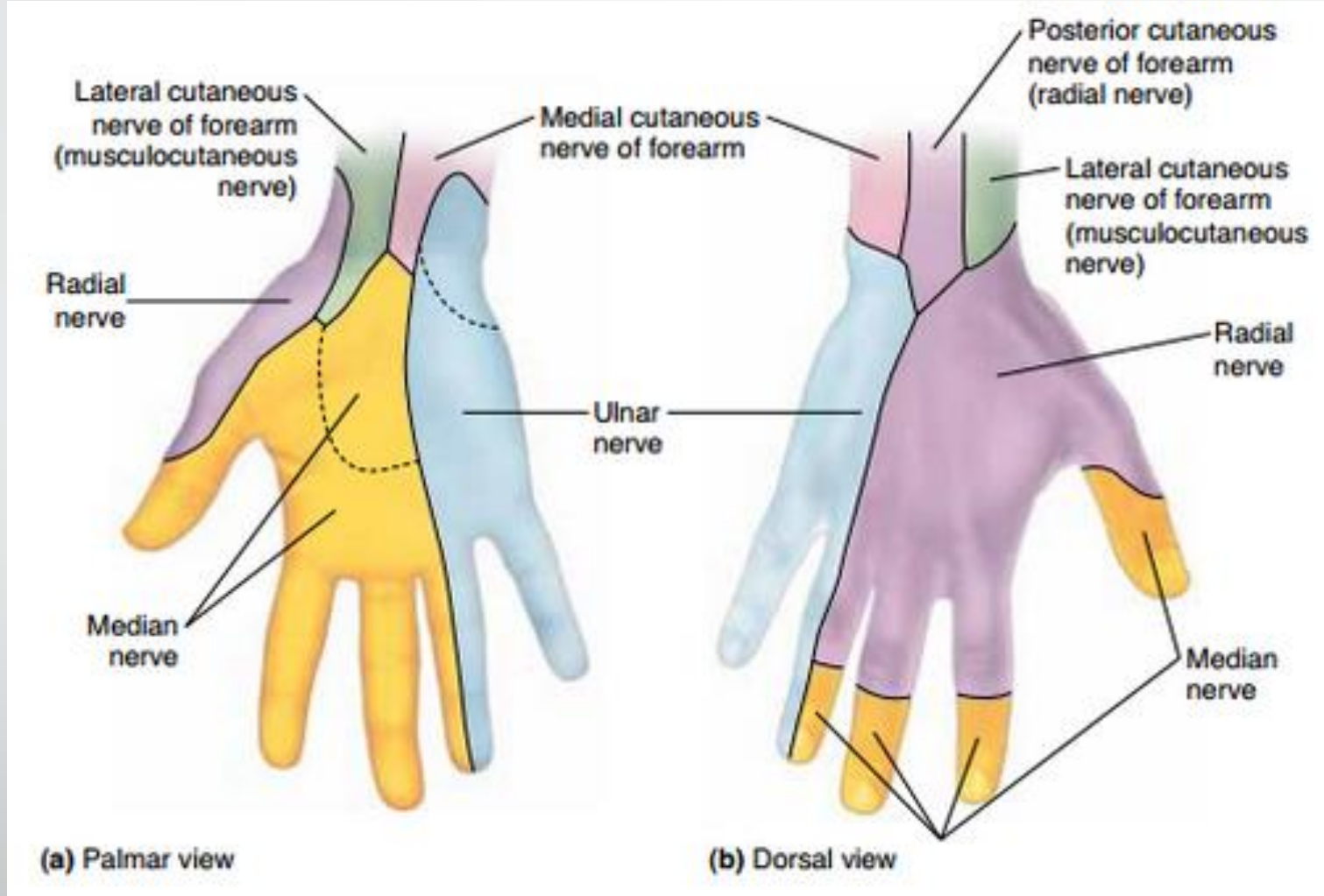


# Elbow

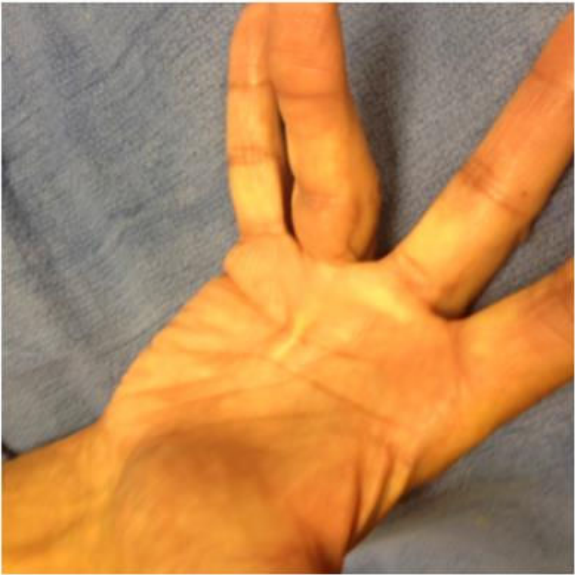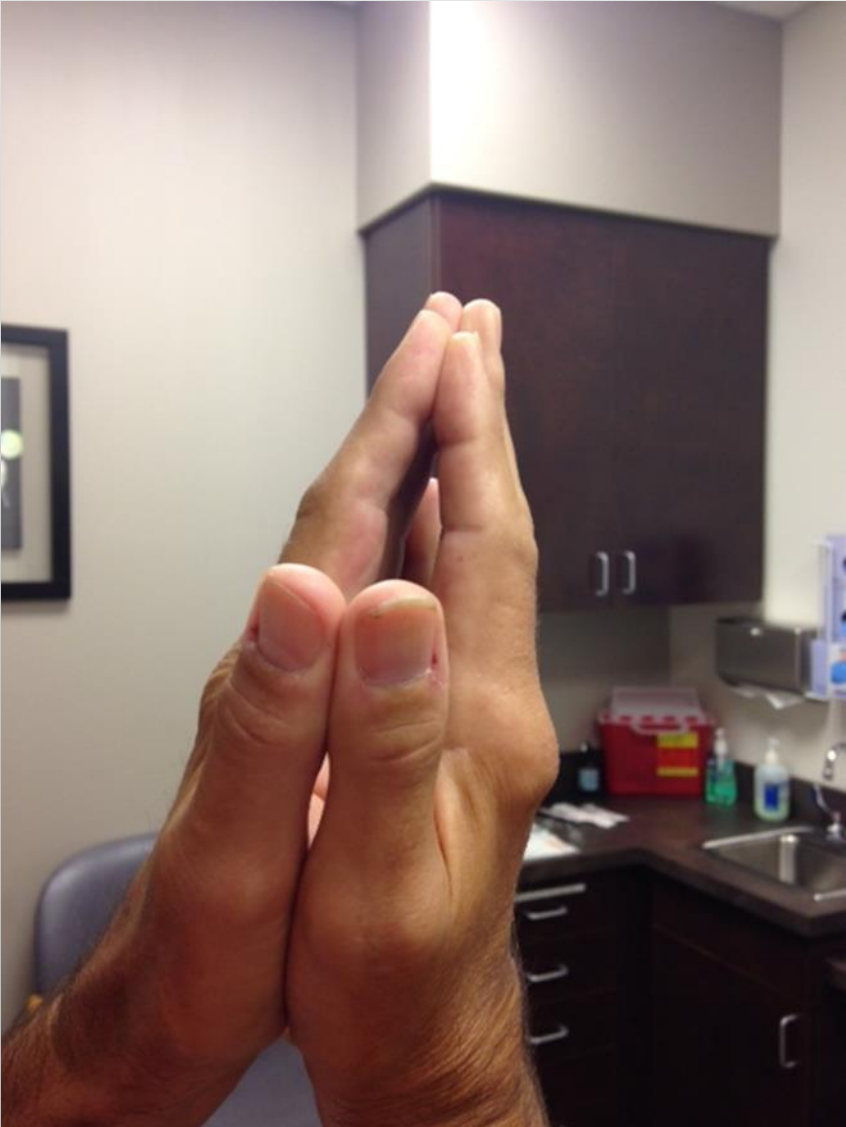- Hinge joint
- Stable with firm bone support
- Joint articulations include the humerus, radius, and ulna
- Special tests: Resisted supination/pronation, resisted middle finger, Tinel at the ulnar groove

# Wrist/Hand

- Bilateral comparison to look for asymmetry
- Inspect for atrophy, joint swelling, triggering of finger
- Special Tests: Tinel, Phalen, Finkelstein, CMC grind
- Include exam of shoulder and elbow to determine etiology (e.g. cervical radiculopathy vs. carpal tunnel syndrome)

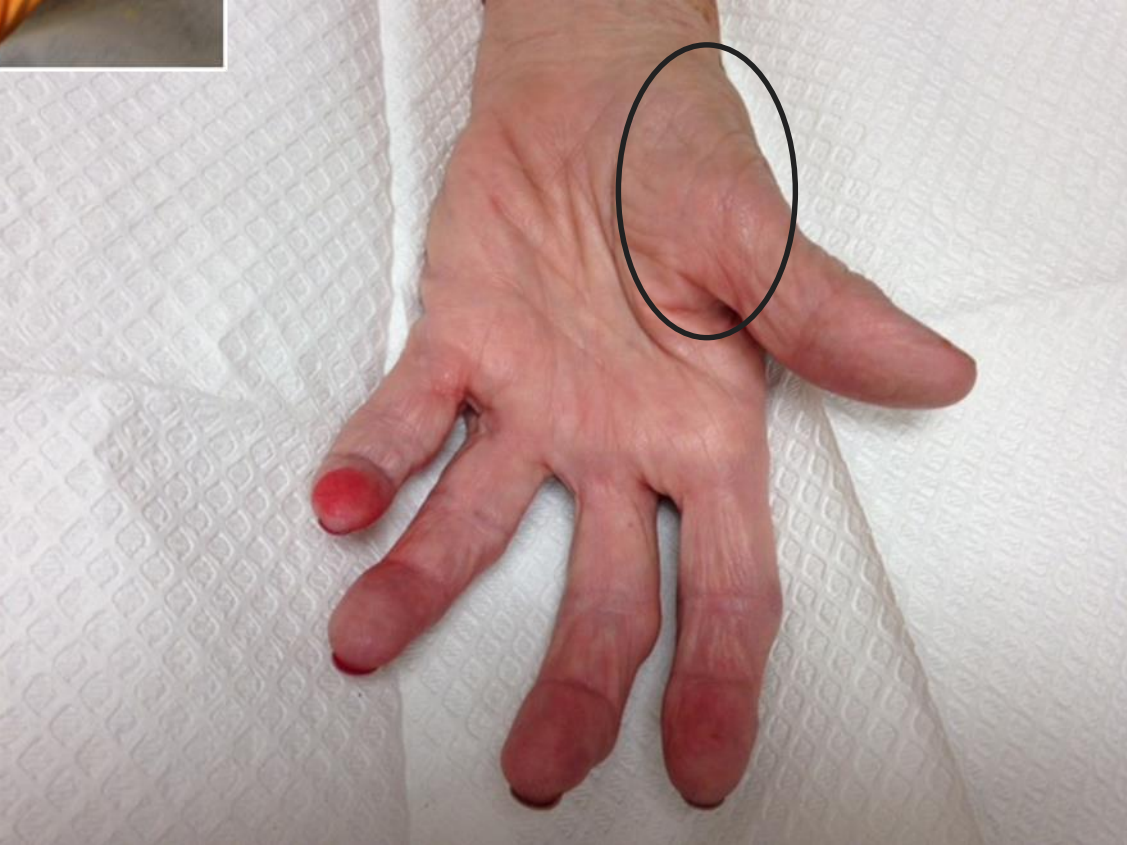

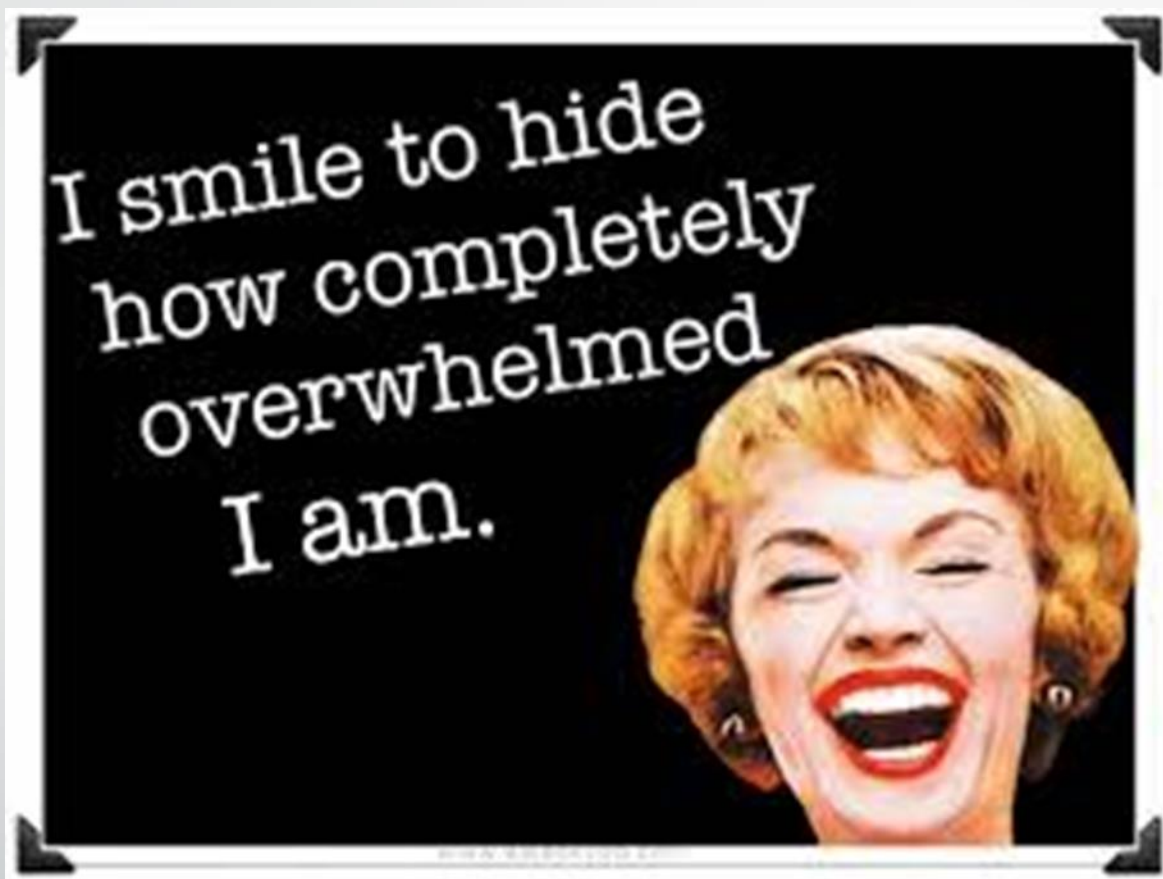Prayer sign



Dupuytren's contracture

Thenar atrophy







Lower Limb

# Hip

Pelvic Girdle: 3 joints

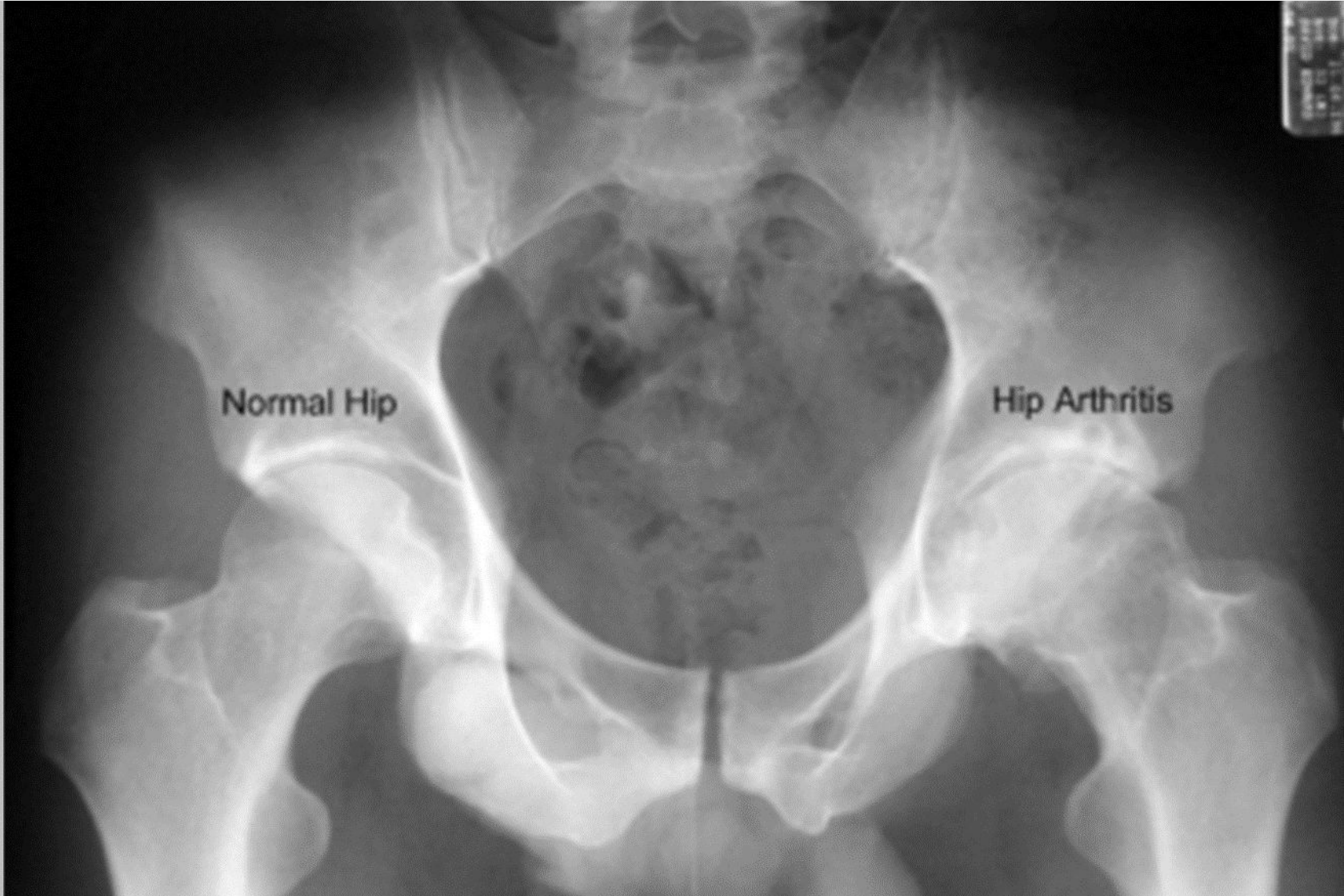
Hip joint

Sacroiliac joint

Pubic symphysis

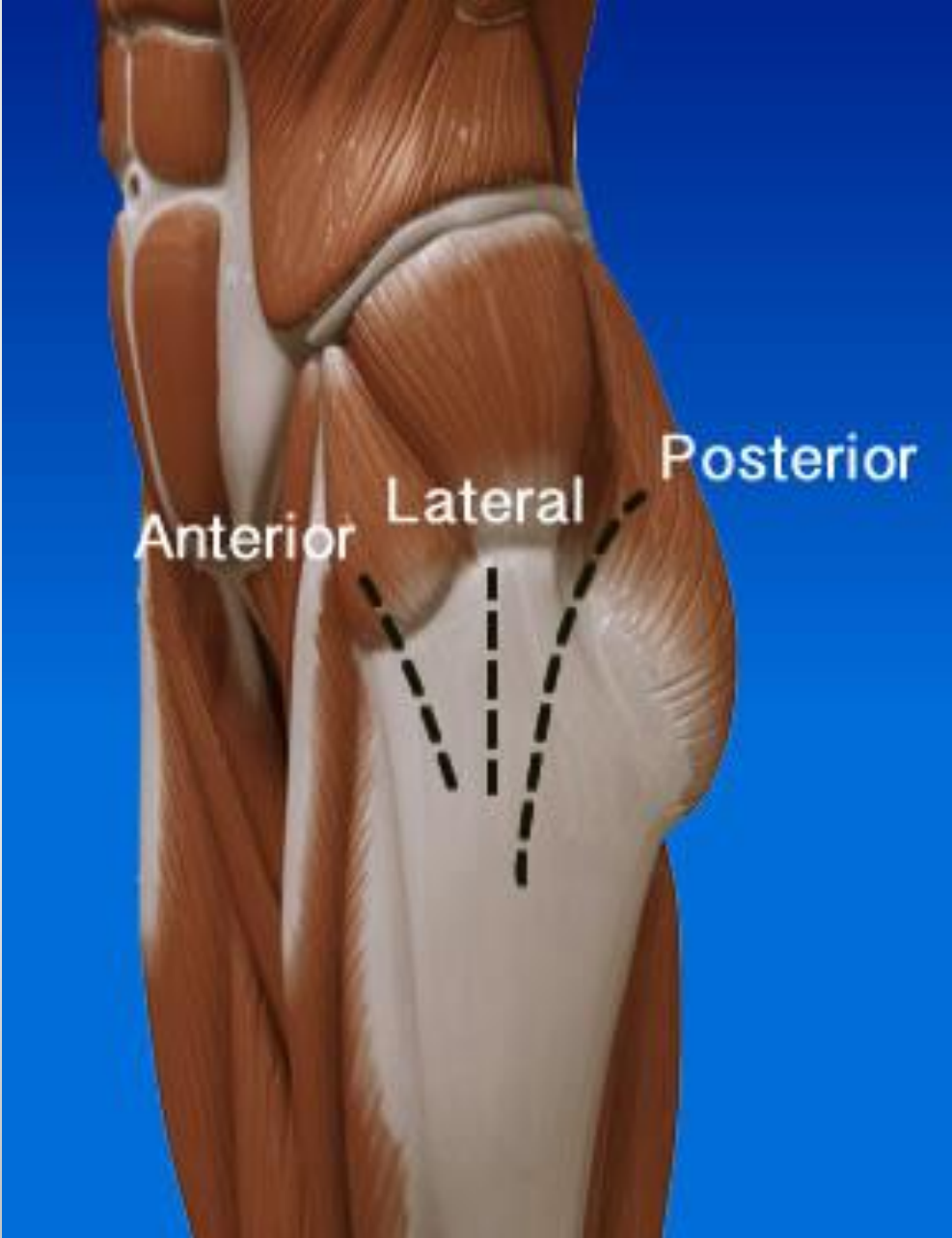

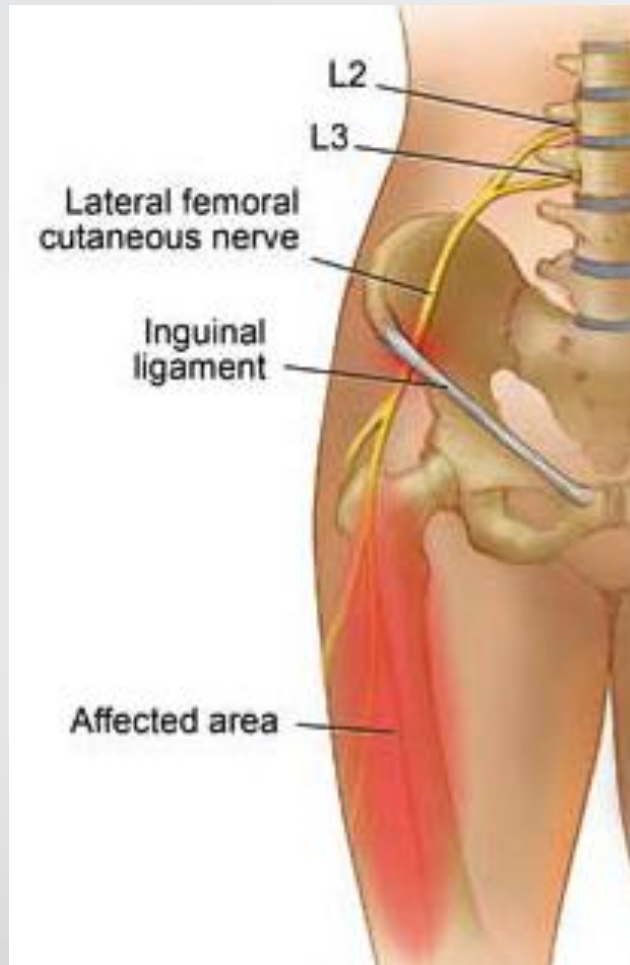




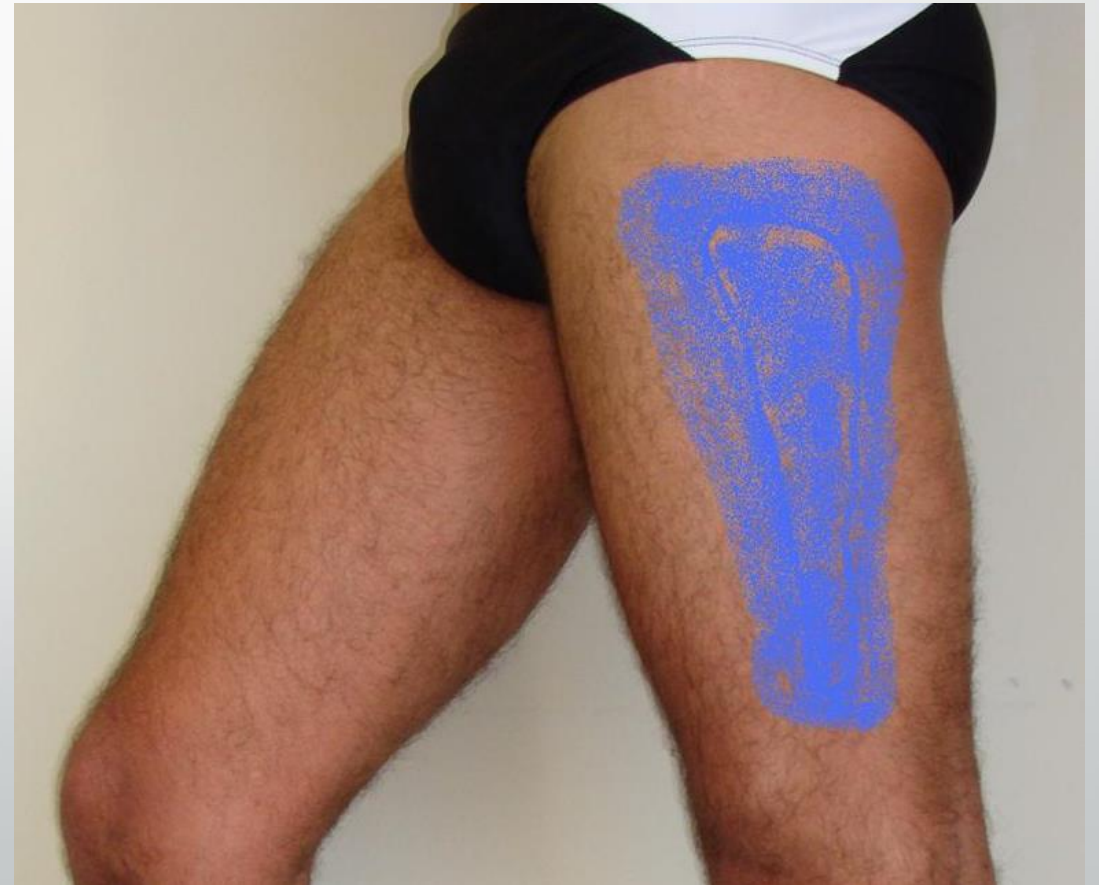# Hip

- Key point: Identify if pain is from hip joint, a surrounding area, or lumbar spine
- Assess anterior, lateral, and posterior hip
- Special tests: Stinchfield (resisted flexion with extended knee), Faber, Gaenslon, Ober

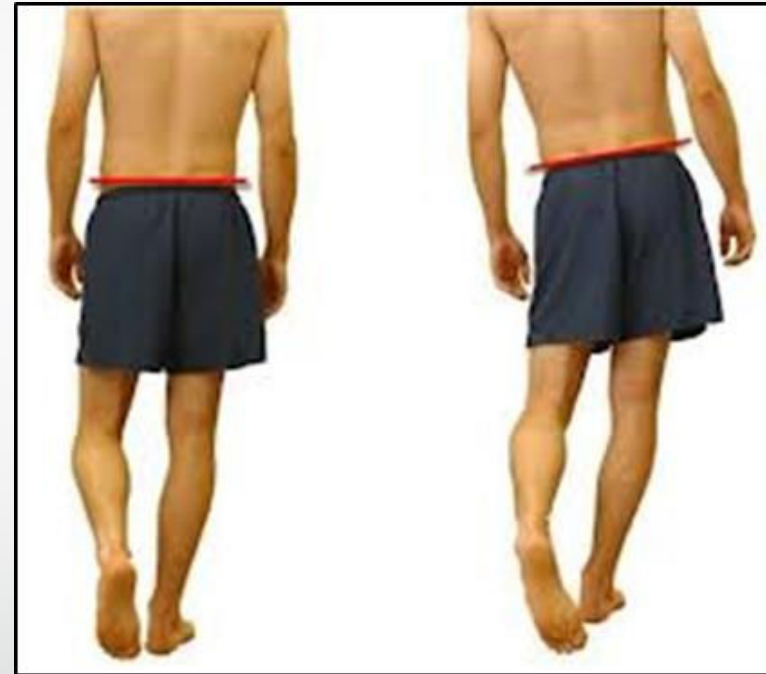



## Meralgia Paresthetica

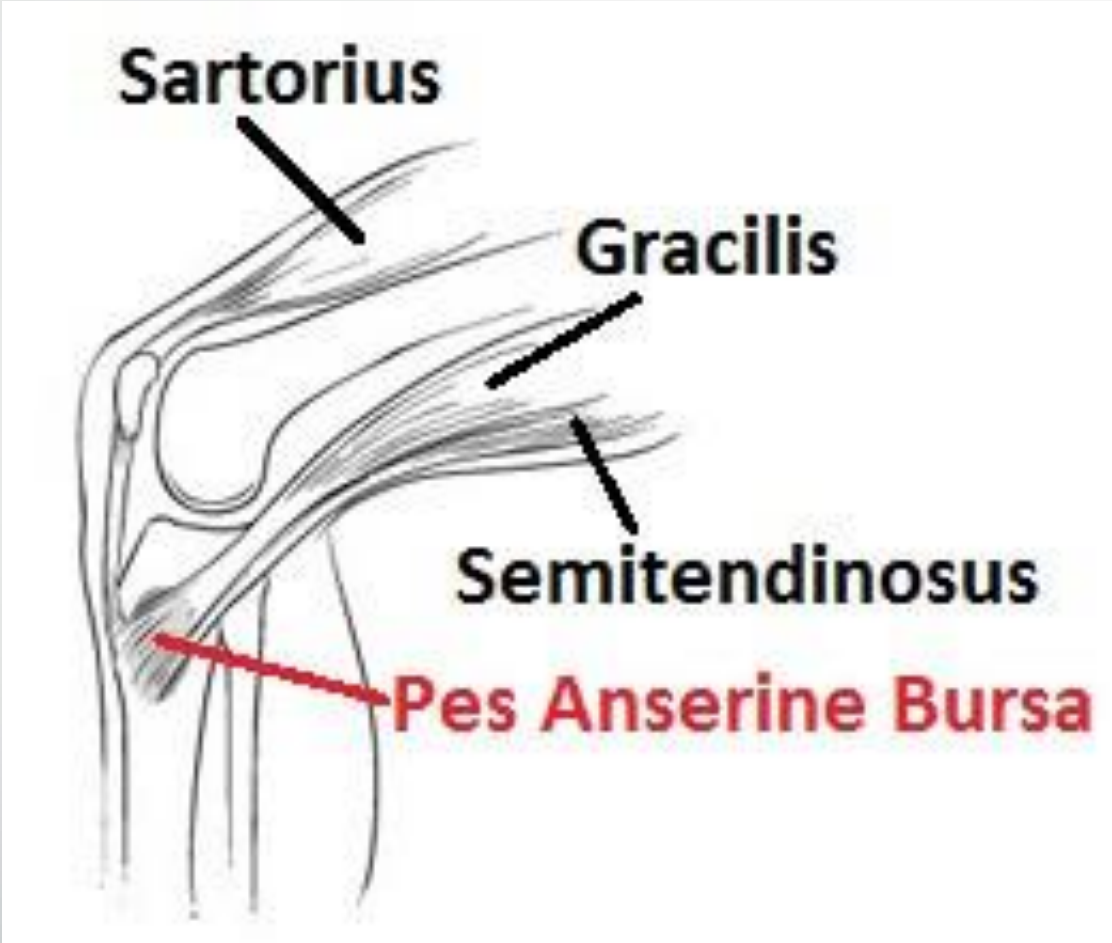


# Trendelenburg Sign

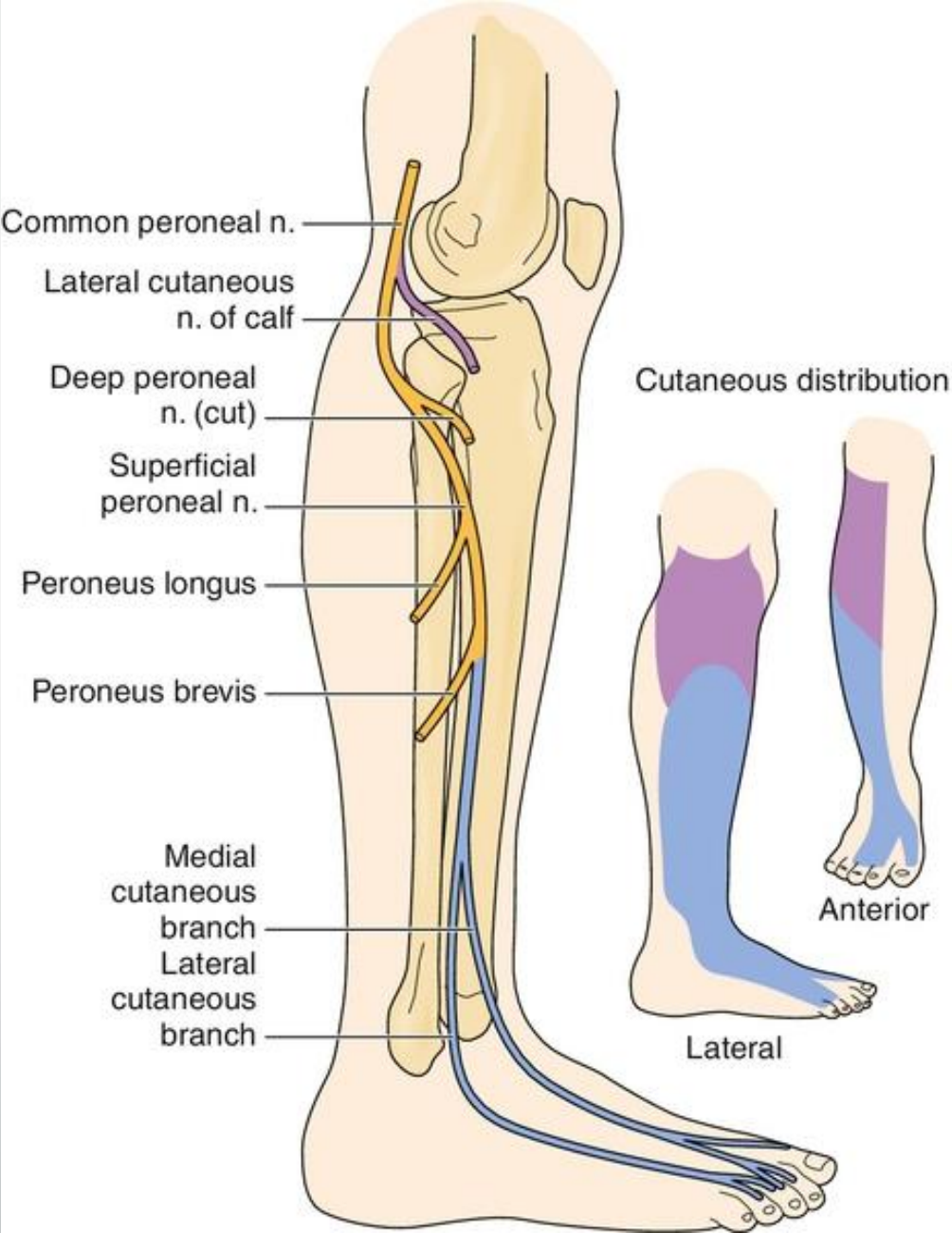


# Knee

- Largest joint in the body
- Modified hinge joint
- Greatest range of motion is flexion
- More exposed joint, therefore higher risk of injury
- Meniscal tear testing (McMurray, Apley)
- Ligament stability testing:
  - Anterior and posterior cruciate ligaments
  - Medial and lateral collateral ligaments



# Peroneal Neuropathy





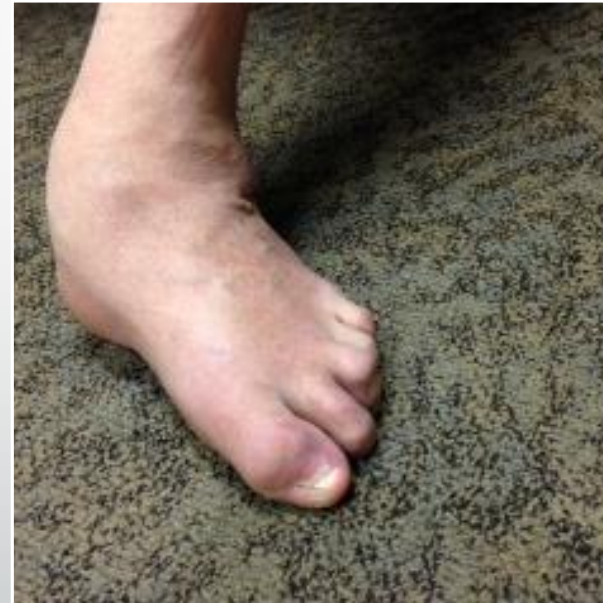# Foot/Ankle

- Foot and ankle are focal points of support for the body to weight bear and ambulate
- Heel and toe pads act as shock absorbers for walking and activity
- Complex joints allow for balance on variable terrain

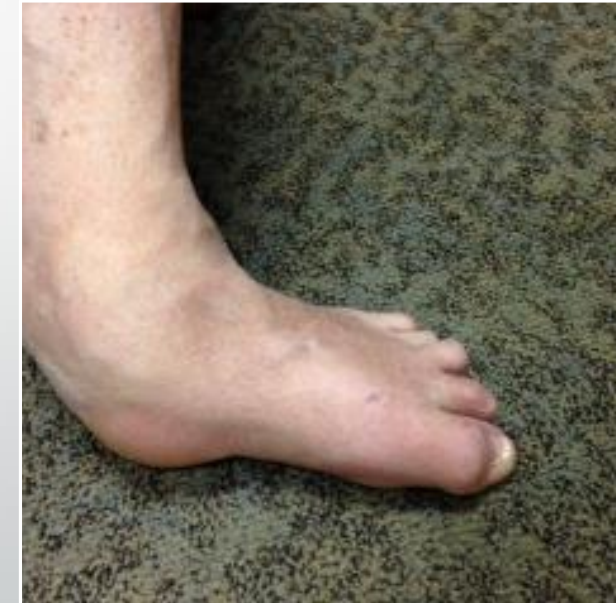# Foot and Ankle

- Include inspection of shoes
- Sensation
- Proprioception
- Arches

Deformed Joint



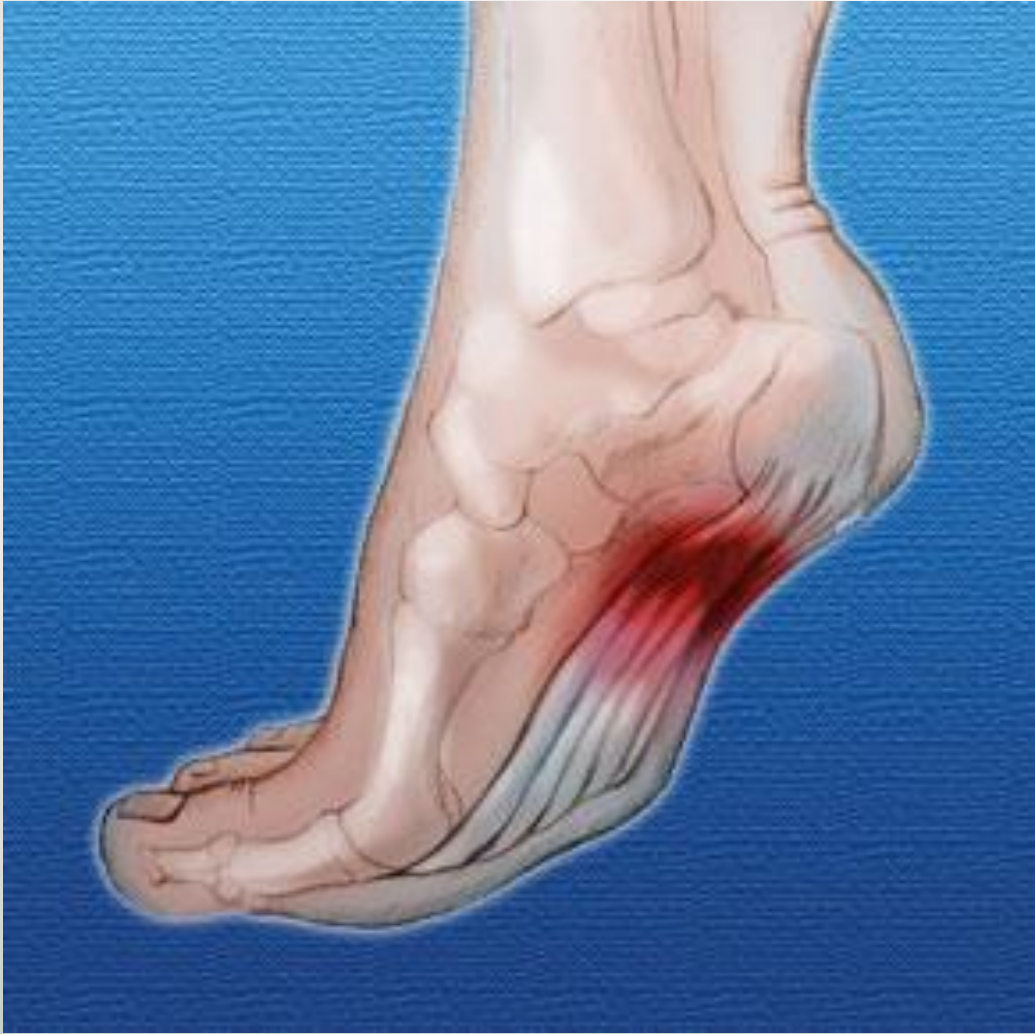Pes Planus



Charcot Joint

# Foot and Ankle

- Plantar fasciitis: tenderness over the medial tuberosity of the calcaneus, tightness with dorsiflexion
- Morton's Neuroma: Squeeze test- usually between 3<sup>rd</sup> and 4<sup>th</sup> metatarsal heads
- Tendinitis: posterior tibial tendon, Achilles tendon
- Bursitis: retrocalcaneal bursa
- Metatarsalgia
- Pes Planus



**SHOULDER EXAM:** No atrophy. Normal strength of rotator cuff and shoulder girdle. Special tests are negative.

Range of Motion: Pain with Internal Rotation, External Rotation, Abduction. Painful arc of motion 80-120 degrees (supraspinatus/impingement).

Special Tests: Positive impingement testing.

**ELBOW EXAM:** No atrophy, no effusion, redness or warmth. ROM is pain-free and within functional limits, normal strength.

Inspection/Palpation:

Tenderness at: lateral epicondyle.

Special Tests: Positive resisted middle finger extension, resisted supination.

**WRIST/HAND EXAM:** No swelling, redness or warmth. No skin breakdown or nail abnormalities. No palmar or dorsal atrophy.

Range of motion is pain free and within functional limits, normal strength.

Inspection: thenar atrophy.

Special Tests: Positive Phalen's, Tinel's, Median nerve compression.

**HIP EXAM:** No atrophy. Inspection/Palpation:

Tenderness at: trochanteric bursa, piriformis, SI joint.

Special Tests: Negative FABER's, Stinchfield's (resisted hip flexion).

**KNEE EXAM:** No atrophy, no effusion, redness or warmth. ROM is pain-free and within functional limits, normal strength. Good ligamentous stability.

**ANKLE/FOOT EXAM:** No swelling, redness or warmth. No skin breakdown or gross deformity. No atrophy. Range of motion is pain free and within functional limits, normal strength. Special tests are negative.

# Make friends with a physical therapist!



# References

Akhtar S, Bradley MJ, Quinton DN, Burke FD. Management and referral for trigger finger/thumb. *BMJ* 2005, 331:30-3.

Brown, K.,L. & Merrill, E. (2015). Musculoskeletal management matters: principles of assessment and triage for the nurse practitioner. *The Journal for Nurse Practitioners*, 11(10), 929-939. <http://dx.doi.org/10.1016/j.nurpra.2015.08.036>

Department of Research & Scientific Affairs, American Academy of Orthopaedic Surgeons. Annual Incidence of Common Musculoskeletal Procedures and Treatment. <http://www.aaos.org/research/stats/CommonProceduresTreatments-March2014.pdf> Published March 2014. Accessed [09/01/2017].

Hoppenfeld, S., & Hutton, R. (1976). *Physical examination of the spine and extremities*. New York: Appleton-Century-Crofts.

Musculoskeletal Medicine. PM&R Knowledge Now. Retrieved on 09/01/2017 from <https://now.aapmr.org/category/musculoskeletal-medicine/>

Sallis, R. (n.d.) Examination skills of the musculoskeletal system. American Academy of Family Physicians. Retrieved on 09/01/2017 from <http://www.ucdenver.edu/academics/colleges/medicalschoo/departments/familymed/education/fellowship/sportsmedfellow/Documents/MS%2oexam.pdf>

Sarwark, J. F., & Carl, R. L. (2010). *Essentials of musculoskeletal care*. Rosemont, IL: American Academy of Orthopaedic Surgeons.

Silva MB, Skare TL.(2012). Musuloskeletal disorders in diabetes mellitus. *Rev Bras Rheumatoly*, 52(4), 594-609.

