

Red and Bumpy and Dry, Oh My!

Kristin Rygg, MPAS, PA-C

Kristin Rygg, MPAS, PA-C

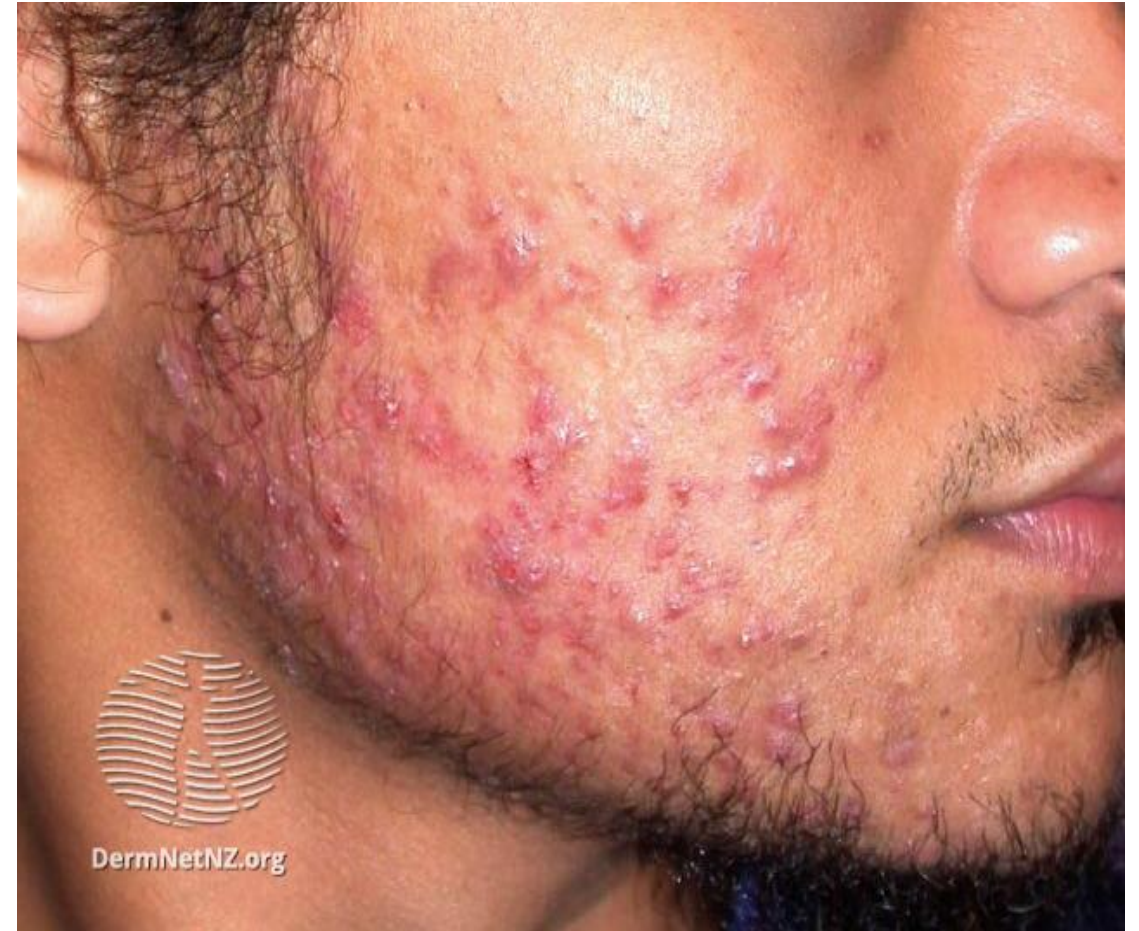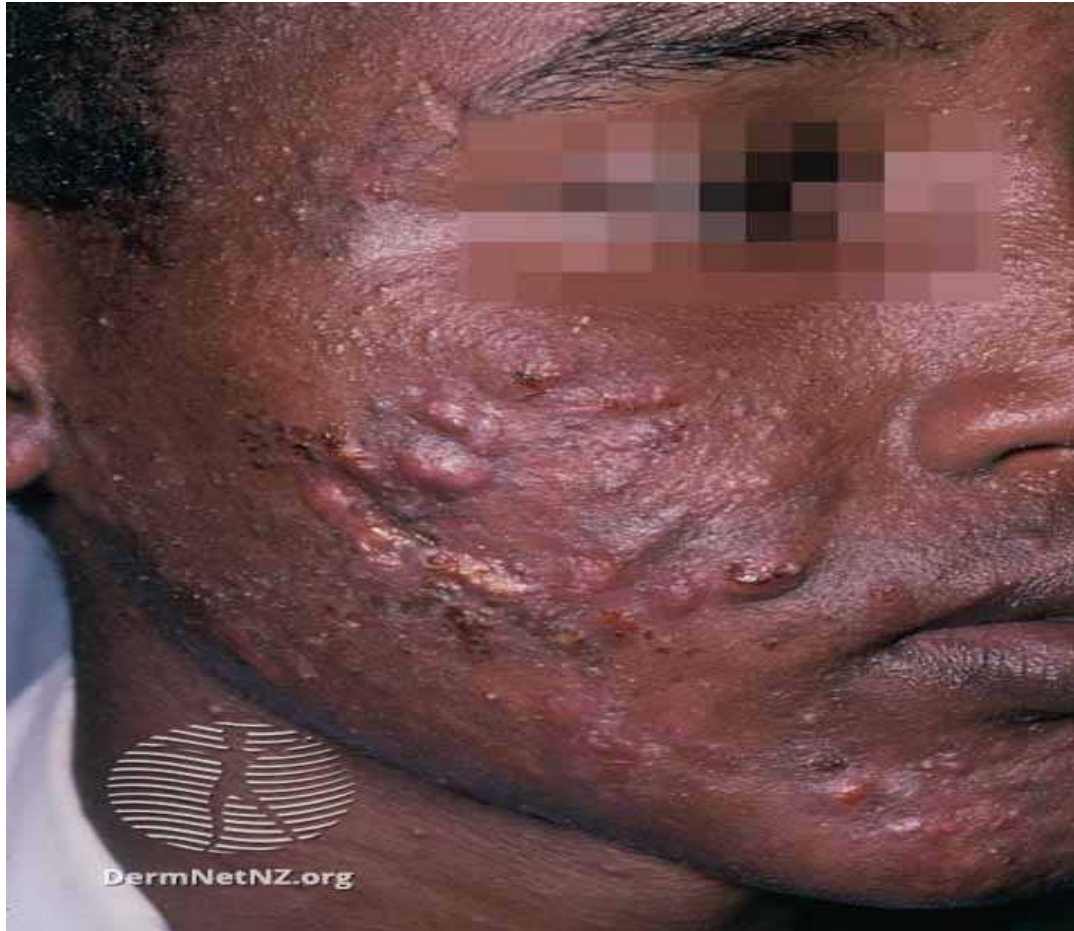- University of Florida, College of Medicine – 2008
- SDPA President Elect, 2024-2025
- SDPA Vice President, 2023-2024
- SDPA Director at Large, 2021-2023
- AAPA Huddle Representative, Dermatology, 2022
- Guest Faculty - University of Colorado PA Program
- Pharmaceutical Speaker
- Denver, Colorado



Presentation Overview

- Acne
- Perioral dermatitis
- Rosacea
- Eyelid Dermatitis
- Lip-licking dermatitis
- Seborrheic dermatitis
- Pityriasis alba

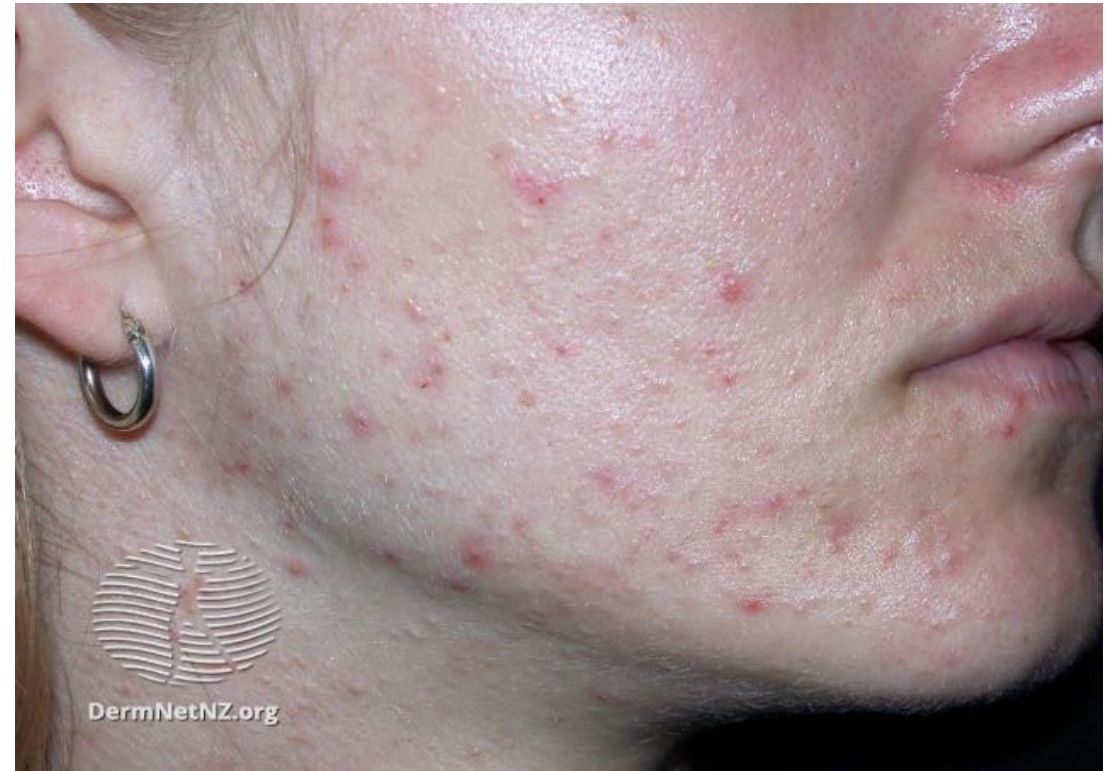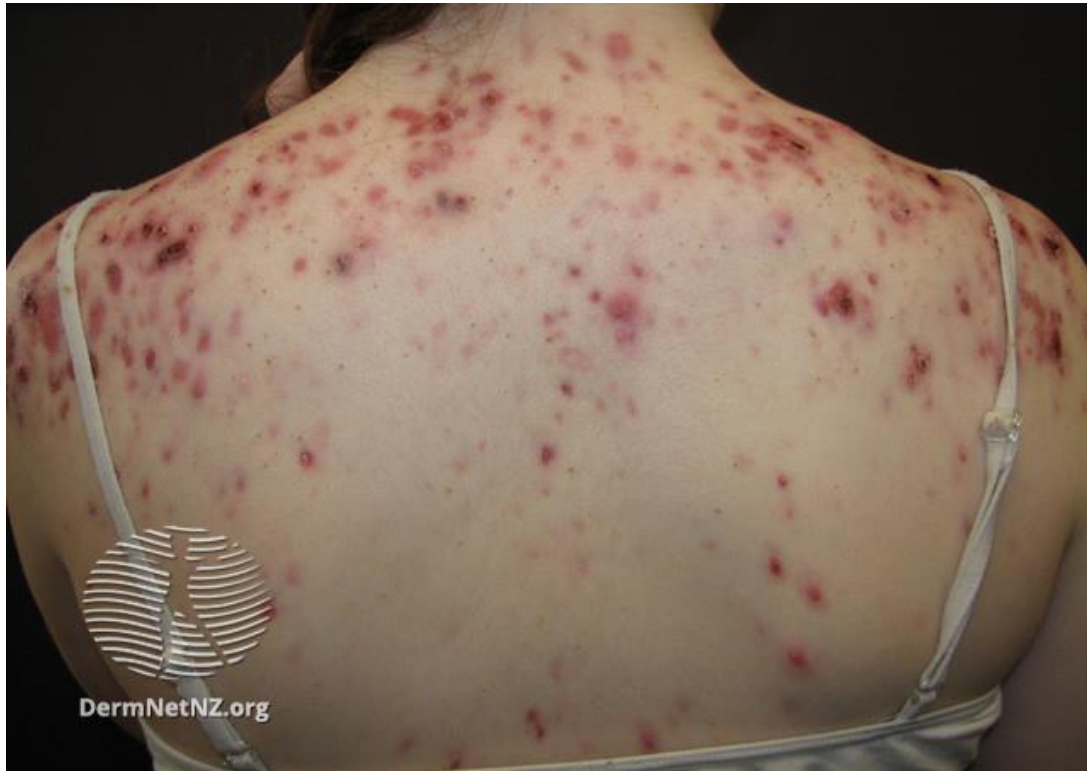Acne



https://dermnetnz.org/assets/collection-O/Nodulocystic-acne/nodulocystic-acne-00008__WatermarkedWyJXYXRlcm1hcmtlZCJd.jpg

https://dermnetnz.org/assets/Uploads/acne/acne-face/acne-face-29__WatermarkedWyJXYXRlcm1hcmtlZCJd.jpg

Acne



https://dermnetnz.org/assets/Uploads/acne/acne-back/146__WatermarkedWyJXYXRlcm1hcmtlZCJd.jpg

https://dermnetnz.org/assets/Uploads/acne/acne-face/acne-face-3-3__WatermarkedWyJXYXRlcm1hcmtlZCJd.jpg

Acne

- Extremely common, usually self limited, chronic inflammatory condition
- Risk factors:
 - increased sebum production
 - follicular hyperkeratinization
 - *C. acnes* (formerly known as *P. acnes*)
 - inflammation that is neutrophil driven
- Starts at puberty
- Found in areas of great density of sebaceous follicles
- Implicated conditions and medications
 - PCOS, Cushings
 - Testosterone, Lithium, immunosuppressants, Jak inhibitors, low-estrogen contraceptives, progesterone only OCP, PTU, steroids

Acne Types

- Neonatal Acne - 2 wks- 3months
- Infantile acne - presents 3-6 months resolved 1-2 years
- Drug Induced
 - within 2 weeks of oral or topical steroid use
 - INH, phenytoin, cyclosporine, lithium, Keflex, OCPs, Androgens
 - Protein powders
- Acne conglobata - Men, late puberty-early adulthood,
 - severe acne, papules, nodules, draining sinus tracts
 - Chest, shoulders, back, nape, buttock.
 - Early intervention warranted

Clinical Appearance

- Face, neck, trunk, shoulders, jawline
- Open and closed comedones, cysts/nodules, papules, pustules, scarring
- Darker skin tones: violaceous or gray lesions as well as persistent PIH

Diagnostic Pearls

- Common triggers: touching, picking, pomade, primers, comedogenic products, occlusive equipment, drugs, makeup brushes
- Hirsutism? Consider hyperandrogenic endocrinopathes
- Drug? Acneiform eruption

Tests

- Clinical diagnosis
- Consider culture or KOH
- Consider referral to endo vs labs: free and total testosterone, FSH, LH, DHEA, prolactin

Severity Drives Treatment

- Mild - non-inflammatory, generally only comedones
- Moderate - beginning of inflammatory lesions; generalized over body; papules, pustules, +/- cystic nodules
- Severe - high risk of scarring; nodules and cysts
- ** number of acne lesions, type of lesions, severity, anatomical site, scarring, QOL

Treatment Considerations

- Cost
- Extent and morphology
- Mechanism of action of medications
- Psychosocial
- Compliance
- Side effects
- Difficult to use several meds at once
- Perception that acne will get worse before it gets better

Acne Counselling

- Chronic disease: goal is control, not always cure
- Lifestyle modifications
- Adverse effects of medications
- Treatment expectations

Behavioral Modifications

- Decrease inflammation, stop picking
- Water based cosmetics and hair products
- Limit occlusion
- Low glycemic diet
- Limit stress
- Establish appropriate expectations

Treatment

- Combination treatment recommended
- Addresses the variety of factors in acne pathogenesis
- Neither topical nor oral antibiotic monotherapy is recommended due to resistance

Treatment

Topical therapy

- 1st line: ~~BPO~~** and/or Retinoid
- 2nd line: Dapsone, Azelaic Acid, Minocycline, Clascoterone, Clindamycin

**warnings issued in 2024.

Oral Therapy

- Antibiotics, OCP, Spironolactone, Isotretinoin

Topical Therapy

- ~~BPO 4-5% wash QD~~
 - Side effects include burning, stinging, redness, irritation
 - **warnings issued in 2024. Ensure you know current warnings before recommending use
- Retinoid TIW - QHS
 - Side effects include burning, stinging, redness, irritation, scaling/peeling
 - Tretinoin gel/cream (0.025%, 0.04%, 0.05%, 0.1%)
 - Adapalene OTC gel (1%)
 - Tazarotene lotion/cream (0.045%, 0.05%, 0.1%)
 - Trifarotene lotion (0.005%)

Topical Therapy cont.

- Dapsone gel (7.5%) QD vs (5%) BID
- Azelaic Acid gel (15%) BID
- Minocycline foam (4%) QD
- Clascoterone cream (1%) BID
- Clindamycin gel/lotion/solution/foam (1%) QD-BID

Oral Antibiotics

- Indicated for moderate-severe inflammatory acne
 - Prudent use to avoid antibiotic resistance
 - Use only in combination with benzoyl peroxide and retinoids
 - Do not use longer than 12 weeks
 - Avoid under age 9
 - Ensure all adult teeth are in

Oral Antibiotics cont.

- 1st line: Sarecycline
 - Targeted towards only skin bacteria
 - Do NOT use with Isotretinoin
 - Weight based
- 2nd line: Doxycycline, Minocycline
 - Can kill more bacteria
 - Common SE: GI upset and photosensitivity
 - Less common SE: dizziness, ataxia, nausea, vomiting, phototoxicity; risks for drug reaction (DRESS)
 - Do NOT use with isotretinoin
- Do not use in children <9 years old as it affects bone and tooth development and may discolor teeth permanently

Oral Contraceptives (estrogen containing)

- Indications:
 - Adult-onset acne in women
 - Peri-menstrual flares of acne
 - Those unresponsive to past therapies
 - Those with symptoms of hyperandrogenism
- Have antiandrogenic effects causing decrease size and functioning of sebaceous glands
- Remember that unopposed progesterone-based contraceptives will often worsen acne

Hormonal Treatments

- Combination OCPs
 - Inhibit androgen synthesis
 - Contraindications: smokers >35 years of age; patients with a history of venous thromboembolism or hypercoagulability
 - FDA approved for acne:
 - Ethinyl estradiol / norgestimate
 - Ethinyl estradiol / norethindrone
 - Ethynol estradiol / Drospirinone
- Androgen receptor antagonists
 - Spironolactone 50-200 mg daily
 - May affect sexual development of fetus
 - May need to check potassium and sodium

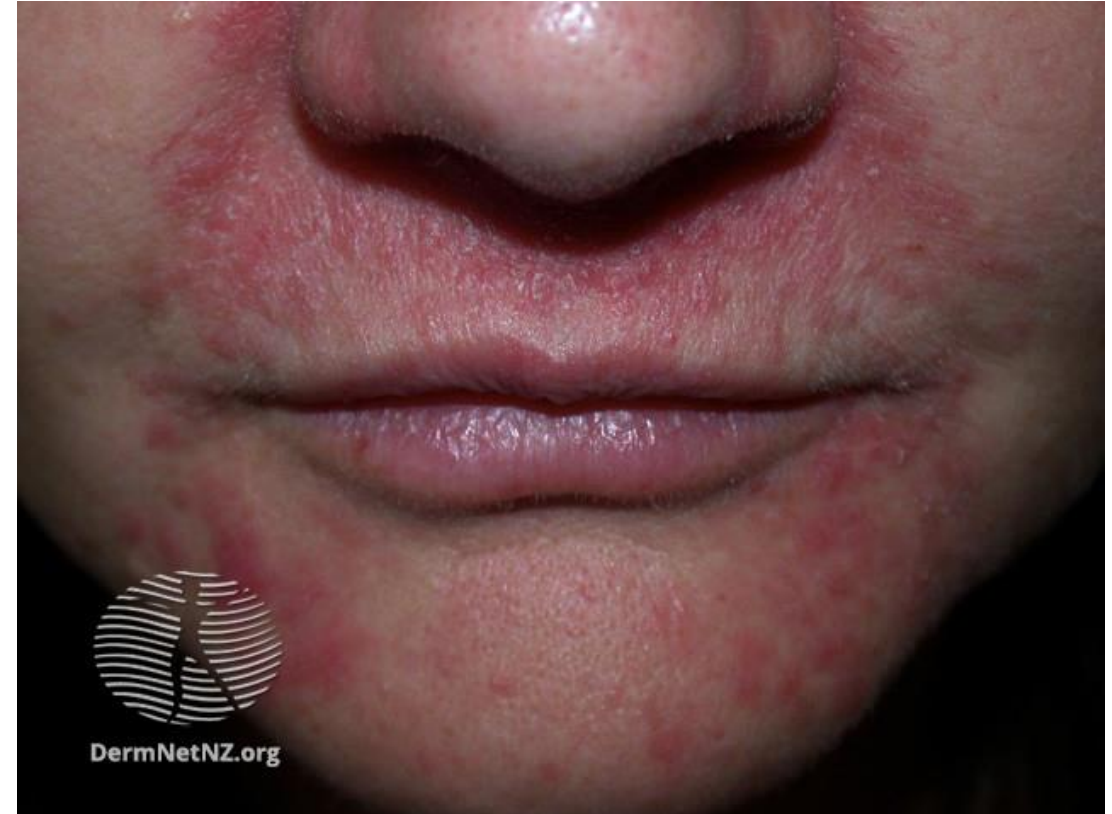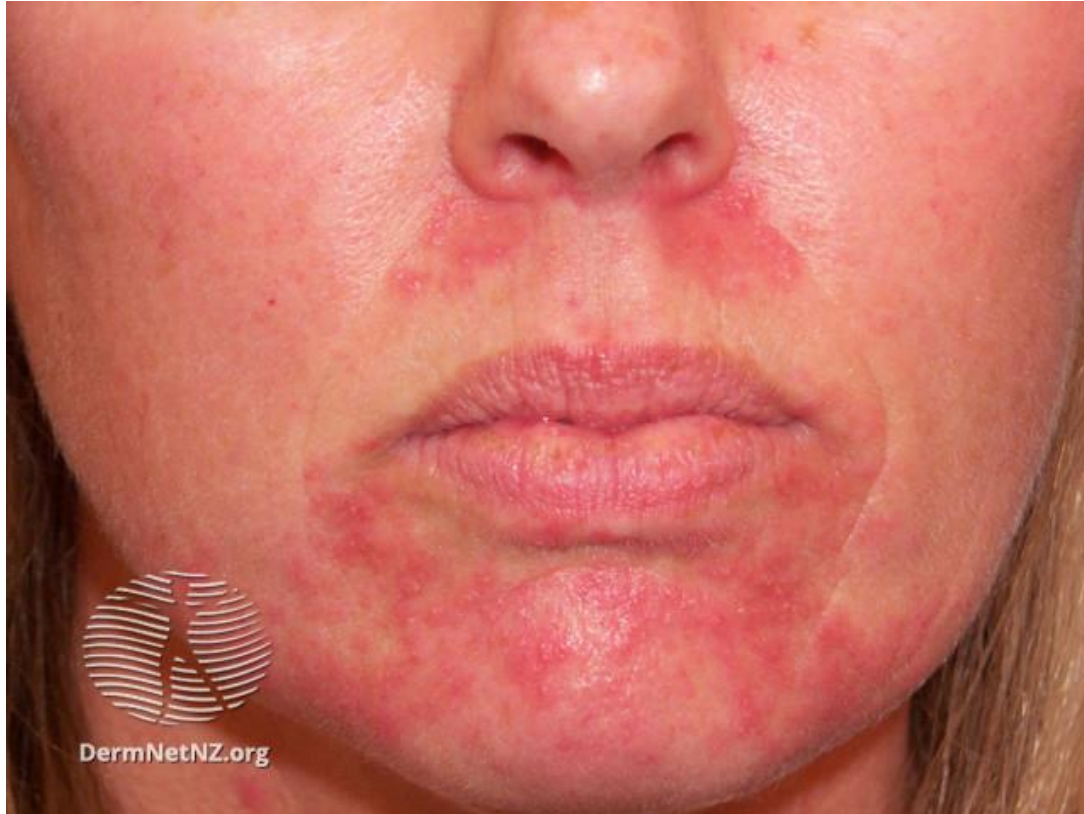Isotretinoin

- Severe recalcitrant acne
- Works on all mechanisms of acne
- Only agent that may have curative potential
- Teratogenic – many congenital defects
 - Two forms of birth control or abstinence required
- iPledge program
- Side Effects
 - May worsen depression and risk of suicide
 - Headache, joint and muscle aches, dry skin/eyes/lips
 - Elevated lipids and liver enzymes

Additional Considerations

- Skin of color
 - Treat both acne and PIH
 - Consider Azelaic Acid, Glycolic Acid, Hydroquinone (limited use!)
 - Medical Aesthetician consult
- Pregnancy / Lactation
 - No medications studied in pregnancy
 - Topical: BPO, Clindamycin, Azelaic Acid, Sulfur washes
 - Always get ok from OB and Pediatrician

Periorifical Dermatitis



<https://dermnetnz.org/images/periorifical-dermatitis-images>

Periorificial Dermatitis

- Inflammatory disorder of face
- Papules and Pustules
- Frequent itching and burning
- Spares vermilion border
- Uncertain etiology
 - topical/oral/inhaled steroids implicated, fluoride, OCP
- Women > Men, Teens to 40s
- Frequently seen at puberty and menopause

Management Pearls

- Taper to stop all topical steroids. Consider Tacrolimus 1%. Warn patients of flare.
- Stop all cosmeceuticals
- Stop mint, cinnamon, charcoal, lip plumpers
- Disposable masks without dye
- Fabric masks with free and clear detergent only
- Topical treatment +/- Oral treatment for two months

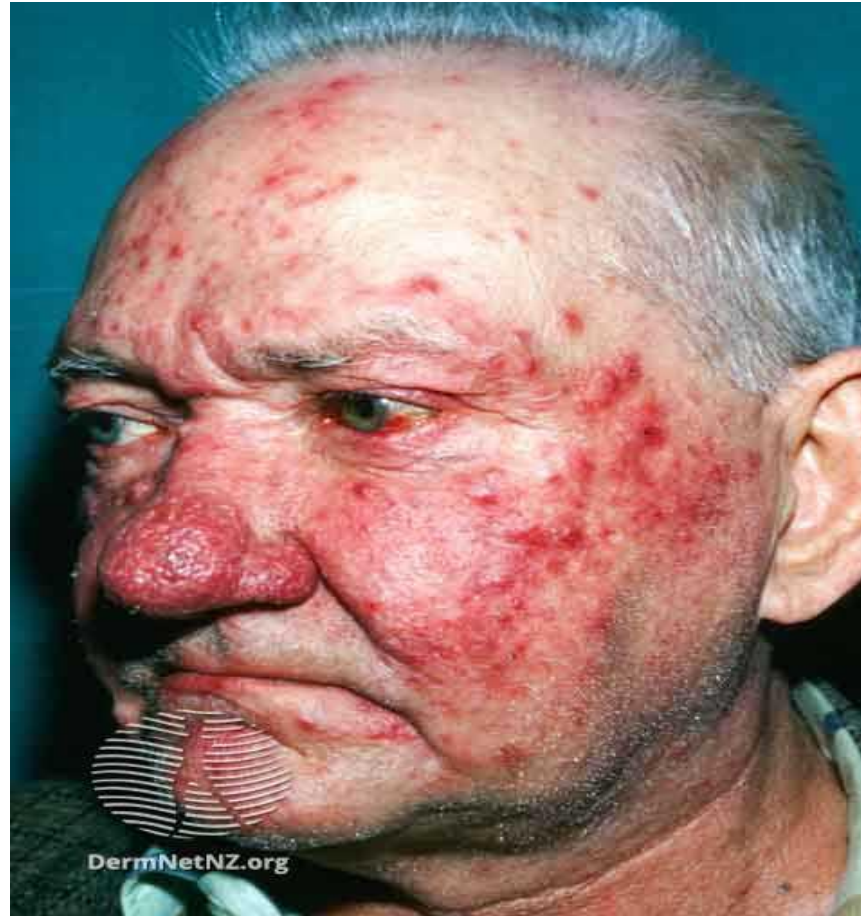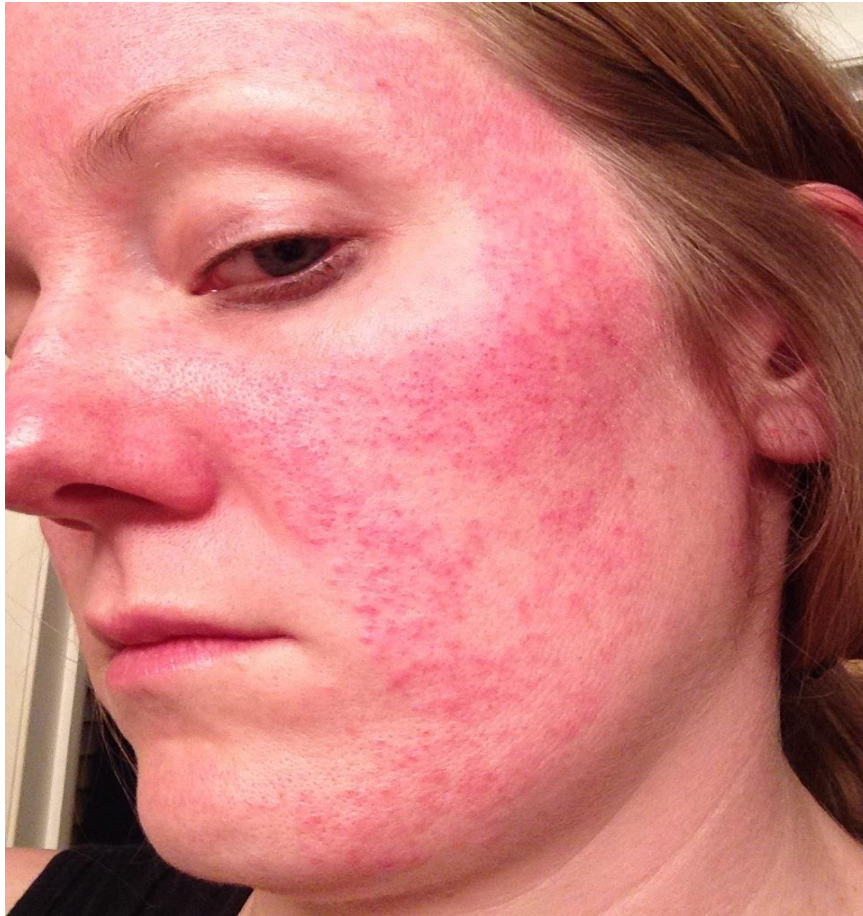Topical Treatment (off label)

- Minocycline (4%) foam BID
- Clindamycin (1%) gel/lotion/foam/solution BID
- Azelaic Acid(20%) gel/lotion BID
- Crisaborole (2%) ointment BID
- Metronidazole (0.75%) lotion/cream BID
- Erythromycin (2%) solution BID
- Tacrolimus (1%) ointment BID (BBW)

Oral Treatment

- Doxycycline 100 mg PO BID x 1 month, then slowly taper
- Erythromycin 333 mg TID x 1 month, then slowly taper
- Isotretinoin at low dose. Refer to dermatology

Rosacea



<https://dermnetnz.org/images/rosacea-images>

Rosacea

- Unclear etiology
 - UV lite, Demodex, S. epidermidis, skin barrier disruption, genetics, drugs
- All skin types, but especially lighter phenotypes
- Chronic, relapse-remit inflammatory condition
- Female > Male, 30-50's
- 4 types, plus granulomatous and rosacea fulminans
 - Erythematotelangiectatic
 - Phymatous
 - Papulopustular
 - Ocular

Clinical Appearance

- Clinical Diagnosis
- Flushing, erythema, papules, pustules, telangiectasias, stinging, burning, dry sensation, eye irritation
- Predominately on cheeks and nose
- Absence of comedones
- Skin of color: violaceous or erythematous to dusky brown, pustules, papules
- *Must not miss Lupus malar rash

Treatment

- Noncomedogenic SPF
- Gentle Cleanser BID
- Avoid Triggers
- Consider ophthalmology and dermatology referral
- IPL and Nd:Yag

Topical Therapy

Papular Pustular

- Metronidazole gel/lotion/cream (0.75%-1%) QD-BID
- Azelaic Acid foam/gel (15%) BID
- Sodium Sulfacetamide with sulfur lotion/cream/wash QD-BID

Demodex

- Ivermectin 1% cream QD-BID
- Permethrin 5% cream QD-BID

Erythema/telangiectasias

- Brimonidine 0.33% gel QAM. Must wash hands
 - Oxymetazoline 1% cream QAM. Must wash hands
- *May get rebound

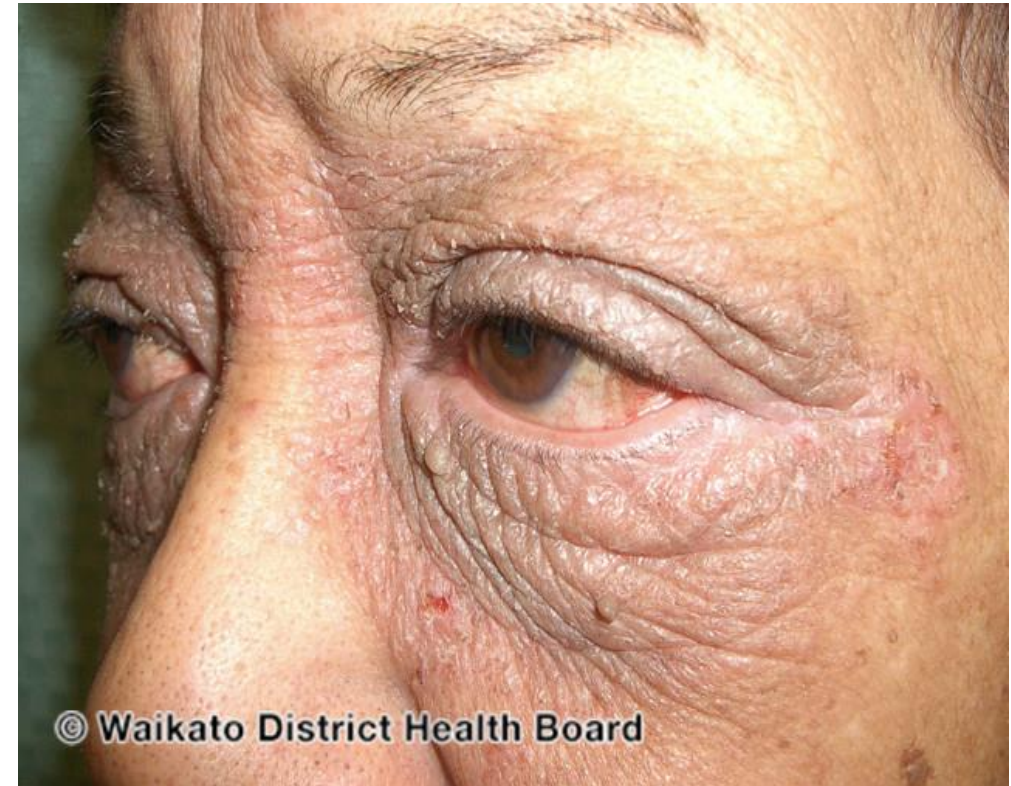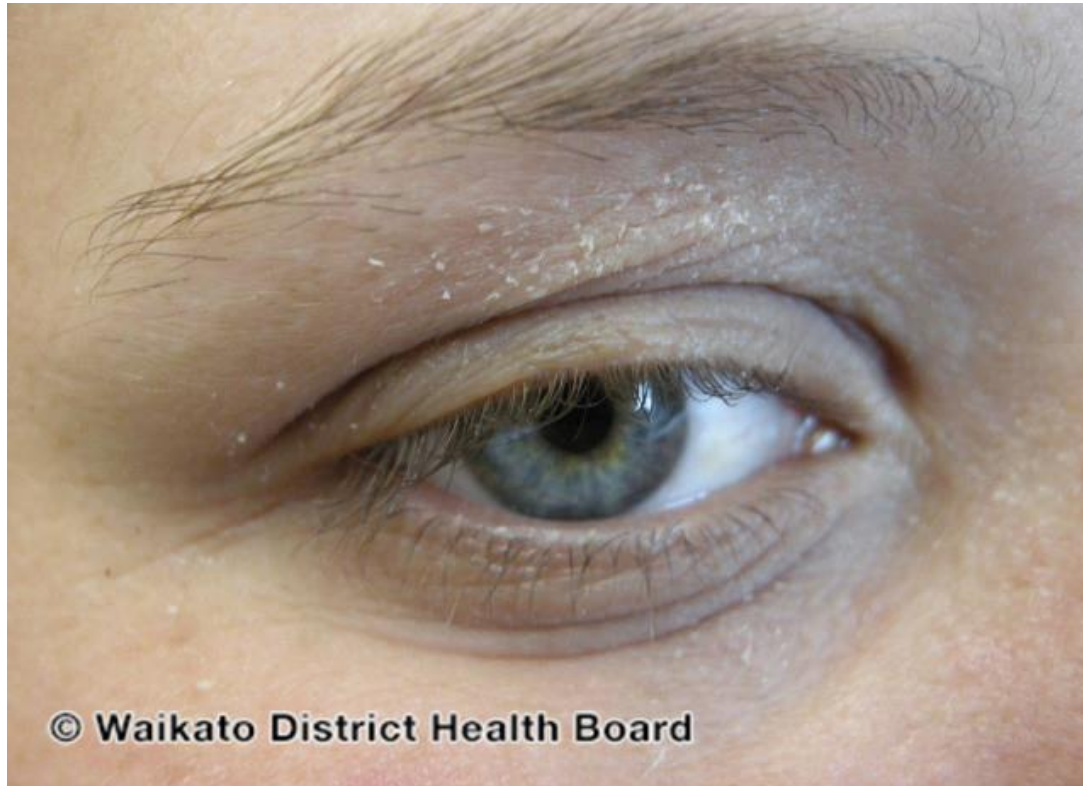Oral and Ocular Therapy

- Doxycycline 40 mg PO QD
- Advanced/recalcitrant cases may require isotretinoin
- Rosacea fulminans: prednisone 1mg/kg and immediate referral to derm

Ocular symptoms

- Oral doxy 40 mg PO QD
- Artificial tears
- Referral to optho

Eyelid Dermatitis



https://dermnetnz.org/assets/Uploads/dermatitis/w/eyelid-dermatitis-01__WatermarkedWyJXYXRlcm1hcmtlZCJd.jpg

https://dermnetnz.org/assets/Uploads/dermatitis/w/eyelid-dermatitis-02__WatermarkedWyJXYXRlcm1hcmtlZCJd.jpg

Eyelid Dermatitis

- Frequently due to atopic dermatitis
- Frequently due to cosmeceutical or overhead chemical
- Chronic, relapsing condition, frequently associated with allergic rhinitis and asthma
- Intense itching is hallmark
- Associated allergy to eggs, cow's milk and peanuts is common

Clinical Appearance

- Scaly patches across and around eyelids
- Frequently will also have dry patches on extensor surfaces
- Acute - erythema, vesicles, weeping, crusting
- Chronic - lichenification, scaling, hypo/hyperpigmentation

Pearls

- Obtain good history
- Ask about known allergens
- Changes in cosmetics, overhead chemicals, plug-ins

Management

- Avoid triggers and stop cosmeceuticals
- Appropriate skin care, bland emollients, avoid dyes/perfumes
- Consider referral to allergy and/or dermatology

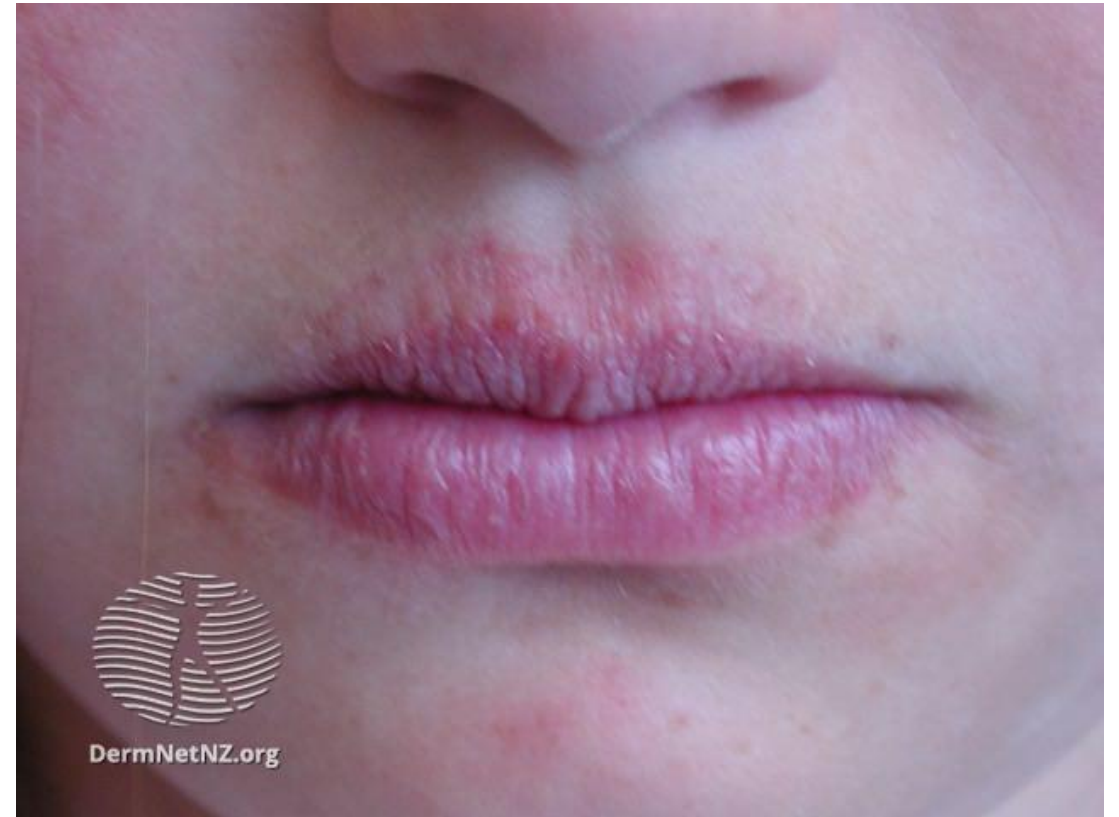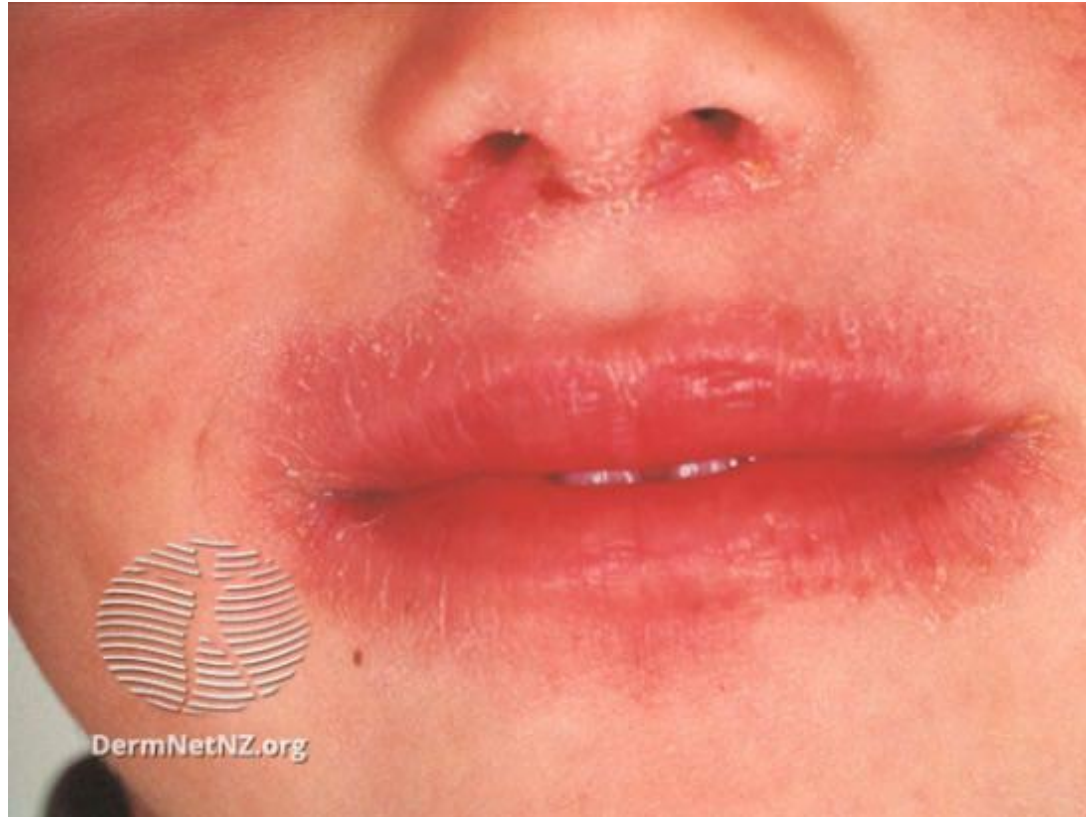Steroid Treatment

- Intermittent low potency topical steroid (class 6-7)
 - Desonide ointment (0.05%)
 - Alclometasone ointment (0.05%)
 - Hydrocortisone ointment (2.5%)
- Steroid BID x 1 week. Stop 1 week. May repeat once then PERMANENTLY discontinue. 15 gram tube, NO refill
- Ensure no history of cataracts or glaucoma
- Write down instructions for proper steroid use

Topical Nonsteroidals

- Crisaborole ointment (2%) BID (3 months and older)
- Tacrolimus ointment (0.3%, 0.1%) BID (BBW, 2 years and older)
- Ruxolitinib cream (1.5) BID (12 yo and older), JAK1/2 inhibitor (MUST discuss warnings)
- Vaseline and Aquaphor
- Treat any secondary infection

Lip-licking Dermatitis



https://dermnetnz.org/assets/Uploads/lip-licker-dermatitis-01-v2__WatermarkedWyJXYXRlcm1hcmtlZCJd.jpg

https://dermnetnz.org/assets/Uploads/lip-licker-dermatitis-2__WatermarkedWyJXYXRlcm1hcmtlZCJd.jpg

Lip-Licking Dermatitis

- Chronic irritant or allergic contact dermatitis due to repeated exposure to saliva and contents
- Clinical diagnosis
- Erythematous, scaly papules coalescing into circumoral plaques, fissures and crusting
- Dark skin types will show hyperpigmentation

Considerations

- Behavior modification
- Eliminate allergens, cosmetics and dental hygiene products as possible
- Consider allergy testing
- Petroleum products only (vaseline or aquaphor)
- Topical steroids (see next slide)
- Treat secondary infections (frequent staph colonization)

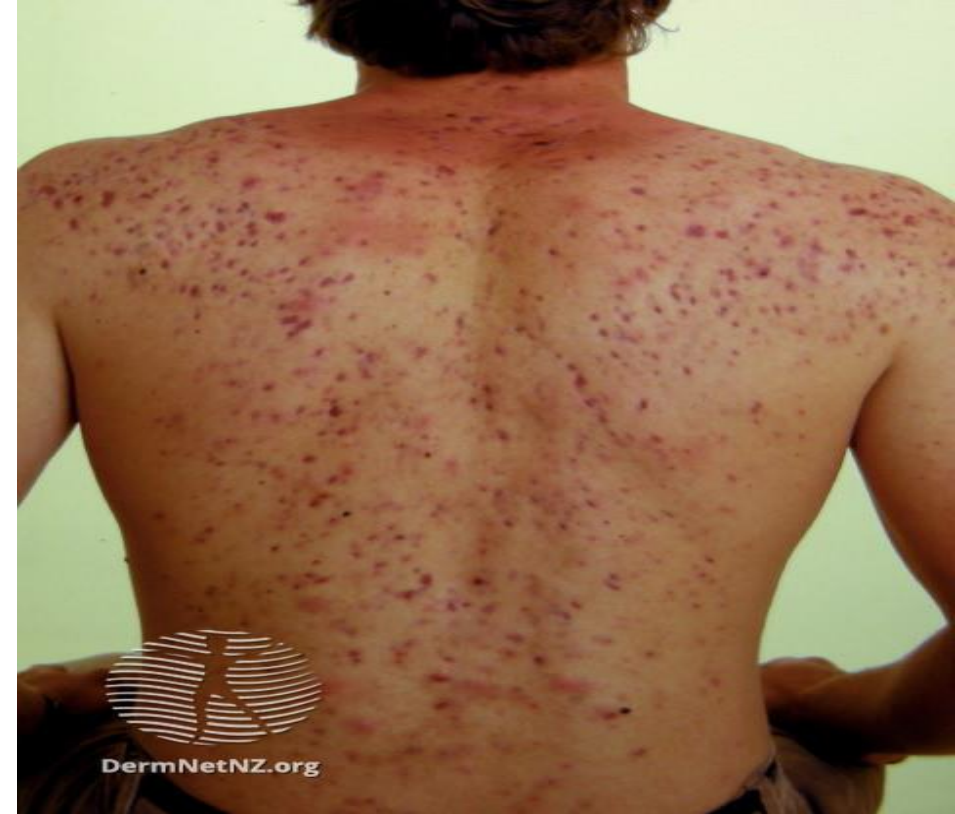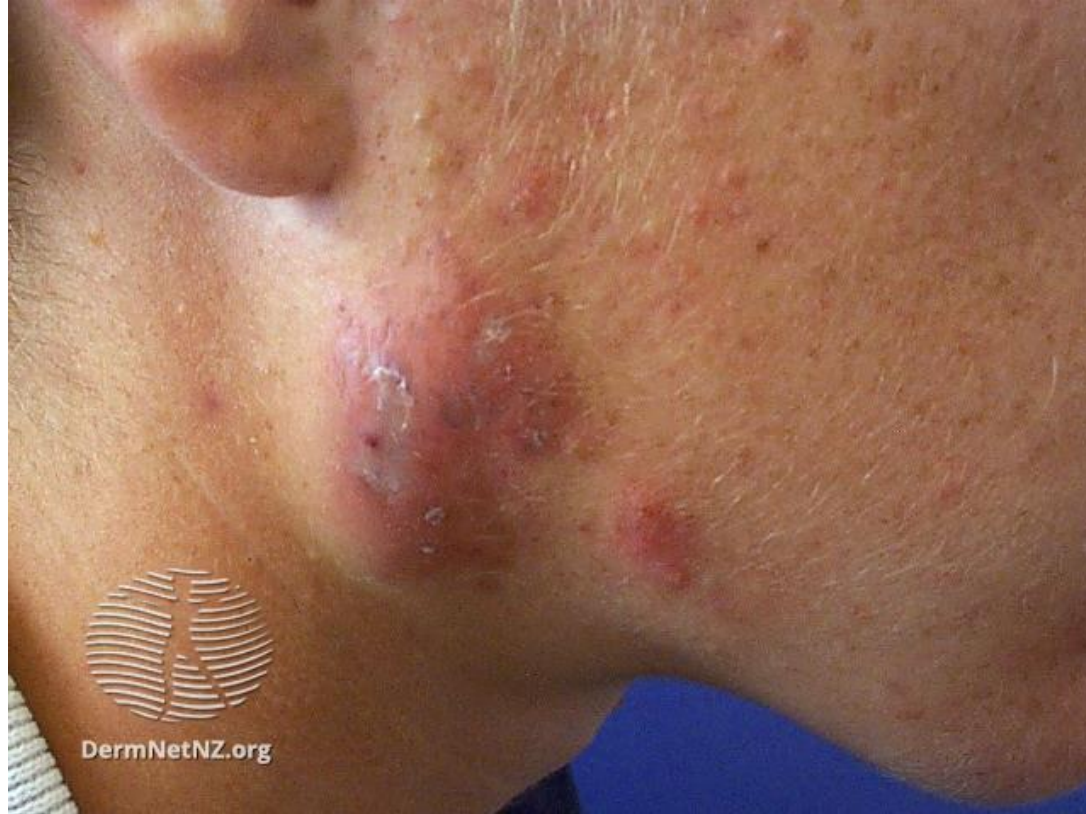Topical Steroids

- Desonide 0.05% ointment
- Hydrocortisone 2.5% ointment
- Acclometasone 0.05 % ointment

- Steroid BID x 1 week. Stop for one week. Repeat once then permanently stop

- Counsel improper steroid use can lead to POD

Cysts



<https://dermnetnz.org/topics/acne-face-images>

https://dermnetnz.org/assets/Uploads/acne/a-conglobata2__WatermarkedWyJXYXRlcm1hcmtlZCJd.jpg

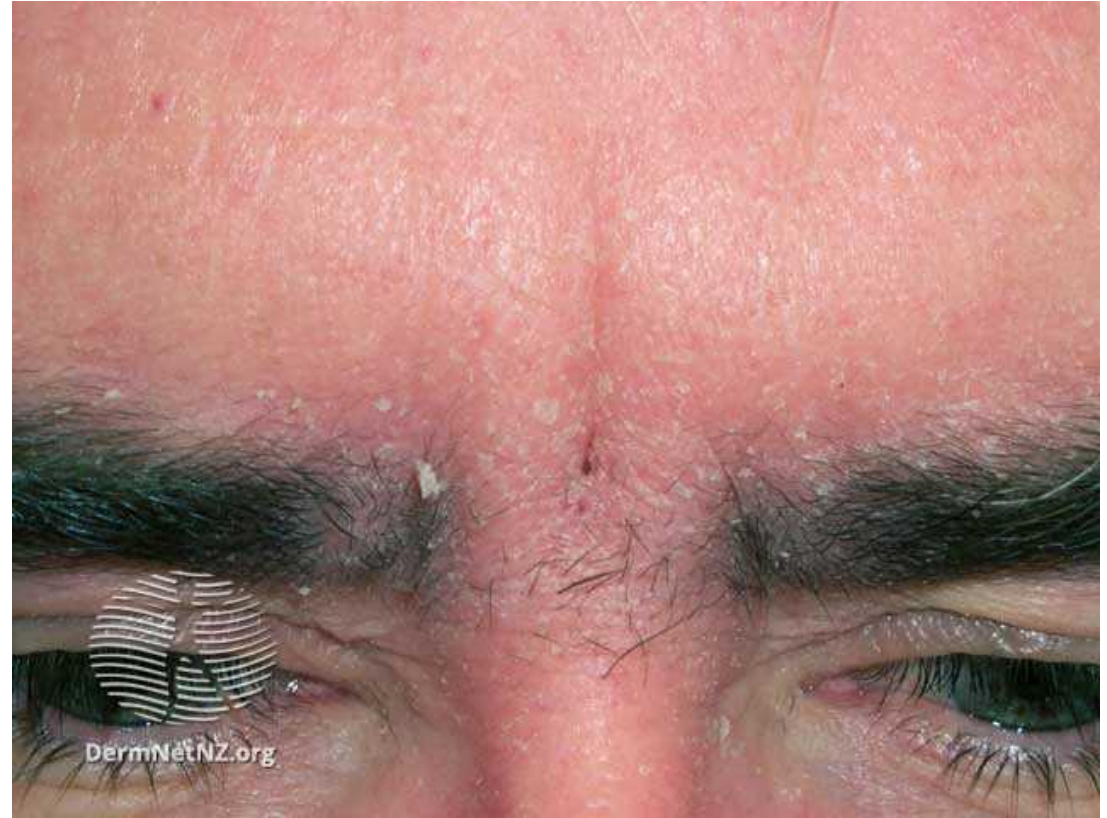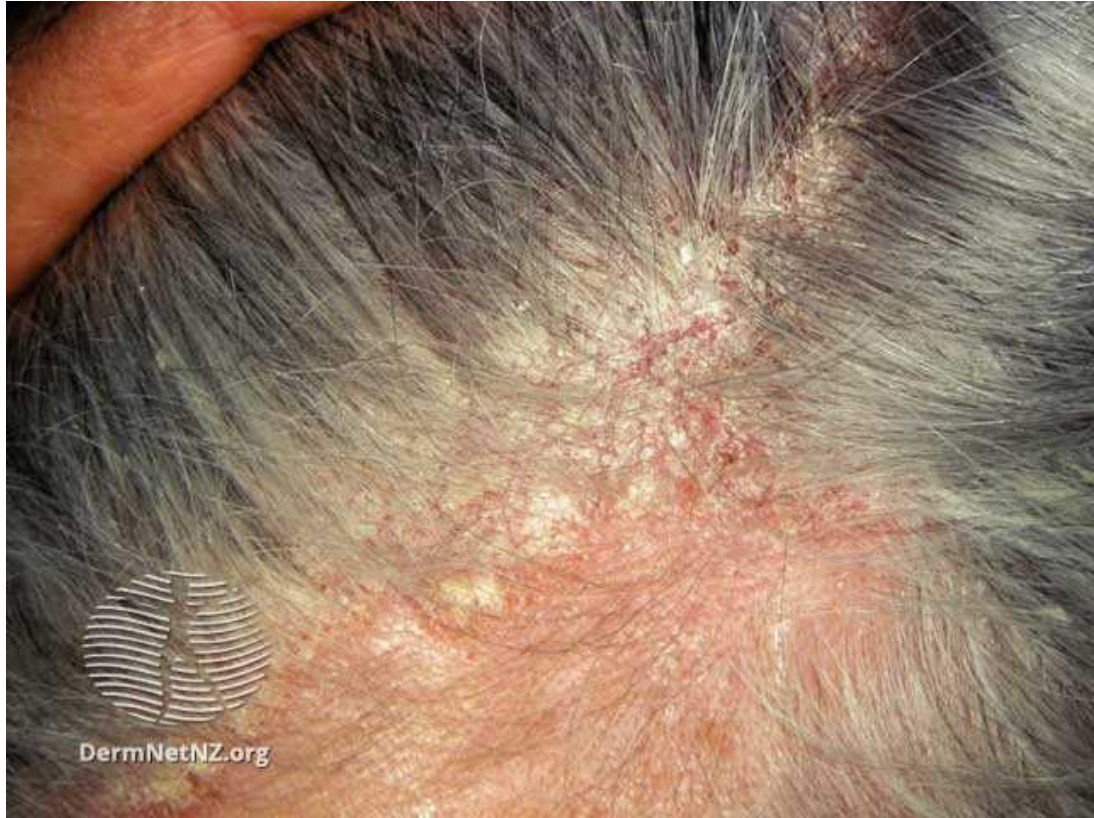Cysts

- Dome-shaped, firm, flesh-colored, may have dilated punctum
- Stratified squamous epithelium and keratin/lipid-rich debris
- Usually benign, asymptomatic unless inflamed/ruptured
- Contents may express with small incision or gentle pressure
- Send sack to pathology

Treatment

- Intralesional Kenalog (2.5%)
 - Inform risk of atrophy and scarring may be permanent
 - Be very careful with darker skin tones
- If inflamed, consider small I&D and culture
- Treat underlying infection
 - Cephalexin 500 mg PO BID x 10-14 days
 - Doxycycline 100 mg PO BID x 10-14 days
 - Bactrim DS PO BID x 10-14 days (rarely if ever use first line due to risk of SJS)

Seborrheic Dermatitis



https://dermnetnz.org/assets/collection/Seborrhoeic-dermatitis/seborrhoeic-dermatitis-0007__WatermarkedWyJXYXRlcm1hcmtlZCJd.jpg

https://dermnetnz.org/assets/collection/Seborrhoeic-dermatitis/seborrhoeic-dermatitis-0009__WatermarkedWyJXYXRlcm1hcmtlZCJd.jpg

Seborrheic Dermatitis: Overview

- Common, symmetric, inflammatory papulosquamous condition
- Erythematous patches and plaques with scale
- Sebum rich areas
 - Face (nasolabial folds, brow, glabella, beard, ears), scalp, ears, upper chest
- Worse with stress, Parkinsons, Hx CVA, immunocompromised
- Chronic condition, relapse/remit
- Generally asymptomatic but may itch, burn
- May present with psoriasis or rosacea

Seborrheic Dermatitis: Treatment

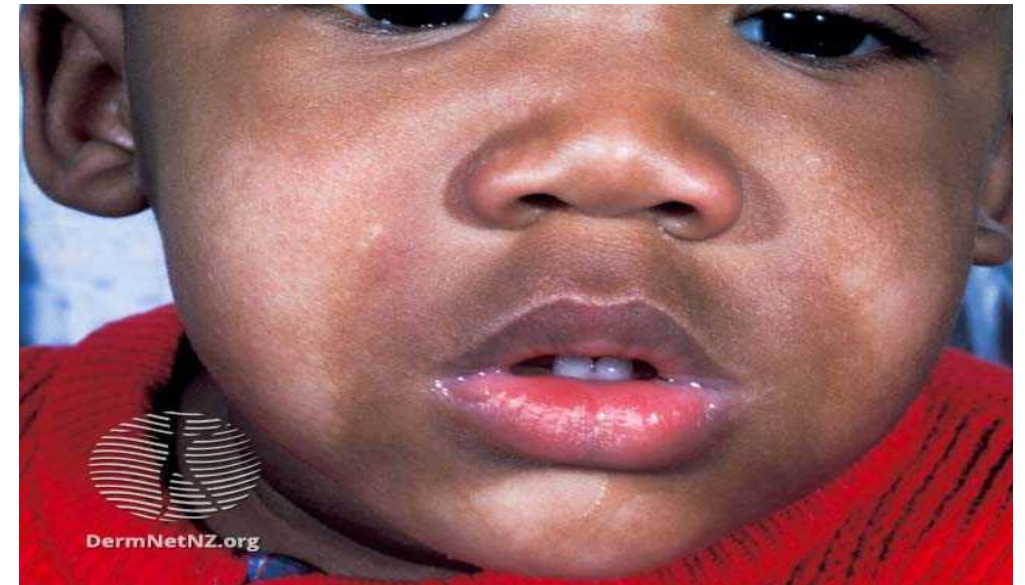
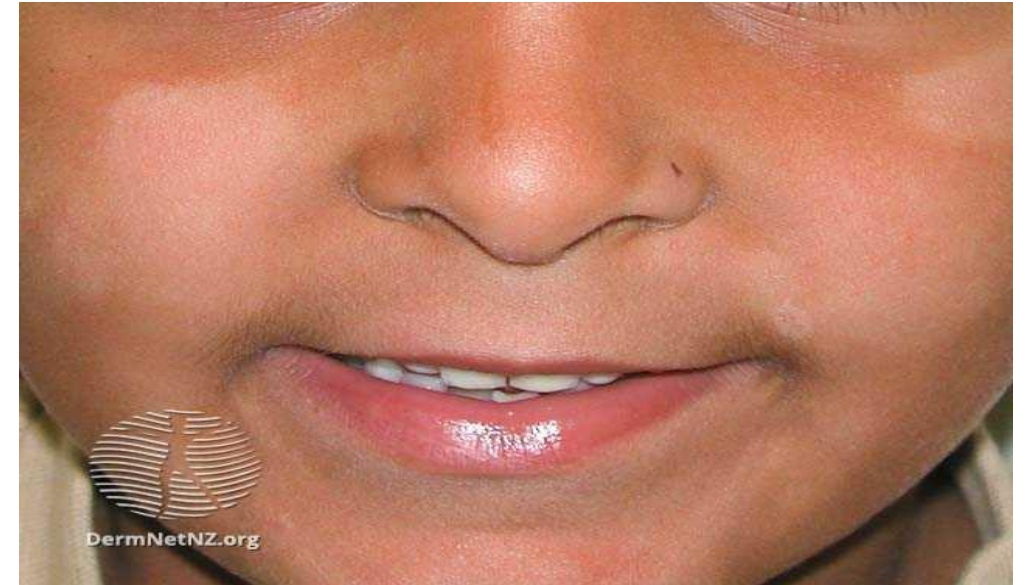- Gentle cleansers
- Antifungal
 - Ketoconazole shampoo daily x 4 weeks, then 3x/week
 - Ketoconazole cream/lotion BID until clear (2-4 weeks)
 - Clotrimazole BID until clear (2-4 weeks)
 - Zinc pyrithione bar (ZNP) 3x/week
 - Ciclopirox Shampoo TIW
 - Sodium Sulfacetamide Sulfa Wash (10/5) QD
- Roflumilast foam (0.3%) QD

Seborrheic Dermatitis: Treatment (cont)

- Low-potency topical steroid (class 6-7)
 - Desonide 0.05% oint
 - Hydrocortisone 2.5% oint
 - Aclometasone 0.05 % oint
 - Steroid BID x 1 week. Stop for one week. Repeat once then permanently stop
- Tacrolimus or Pimecrolimus BID
 - BBW
 - Two years of age or older
- *Reserve steroids for FLAIRS only
- *Do NOT give combo betamethasone/clotrimazole

Pityriasis Alba

- Mild form of atopic dermatitis
- Commonly affects children
- Chronic relapse/remit
- Worse in summer
- Poorly demarcated pale pink, light brown, white macules and patches, subtle scaling



Pityriasis Alba: Treatment

- Consider KOH
- Dry skin care regimen
- Emollients
- SPF 30+
- Topical steroids
 - Low potency (class 6 – 7)
 - Desonide 0.05% oint
 - Hydrocortisone 2.5% oint
 - Acclometasone 0.05 % oint
 - Steroid BID x 1 week. Stop for one week. Repeat once then permanently stop
- Nonsteroidal agents
 - Crisaborole ointment (2%) BID
 - 3 months and older
 - Tacrolimus ointment (0.3%, 0.1%) BID
 - BBW
 - 2 years and older
 - Ruxolitinib cream (1.5) BID
 - BBW
 - 12 yo and older
 - JAK1/2 inhibitor

Q & A