



NOT JUST CHILD'S PLAY: A REVIEW OF PEDIATRIC ORTHOPEDICS

Jerry Weniger, PhD, ATC, PA-C

Director, Physician Assistant Program
Associate Professor, Health Professions Dept.
James Madison University

DISCLOSURES

I have no personal or financial interests to declare.

I receive no financial support from industry sources.

PRE-TEST QUESTION #1

A 5-year-old boy is being seen for a limp. The parents note that the boy has been gradually refusing to run. There has been no rash or fever. He exhibits an antalgic gait and has limited hip ROM. X-rays were normal. MRI shows signal changes in right femoral head consistent with decreased perfusion. What is the most likely diagnosis?

- A. Slipped capital femoral epiphysis
- B. Osteomyelitis
- C. Transient tenosynovitis
- D. Legg-Calve-Perthes disease

PRE-TEST QUESTION #2

A 4-year-old girl refuses to use her right arm after her Dad tugged on her arm to keep her from falling as they stepped off from a curb. She is in no distress, but is holding her arm against her chest in pronation and slight elbow flexion. What is the next best step?

- A. Hyper-pronate her forearm while applying pressure to the radial head
- B. Obtain X-rays of the elbow & forearm
- C. Place the patient in a splint and refer to Ortho
- D. Using fluoroscopy, perform arthrocentesis of elbow

PRE-TEST QUESTION #3

A 13-year-old boy presents with gradually worsening right knee pain. He is on the soccer team at school and notes his pain is worse after practice. His knee is tender to palpation over his tibial tuberosity. There is no joint effusion nor ligamentous laxity. His pain is worst with resisted knee extension. What is the next best step?

- A. Corticosteroid injection at patellar tendon insertion
- B. Place him in a knee immobilizer and crutches
- C. Recommend NSAIDS and activity as tolerated
- D. Refer to Ortho for surgical intervention

OSGOOD SCHLATTERS DISEASE

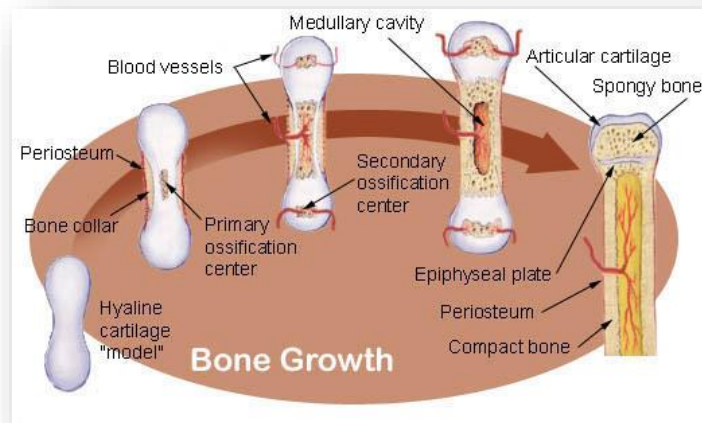
- But first...

What is an ossification center?

BACKGROUND ON OSTEOLOGY

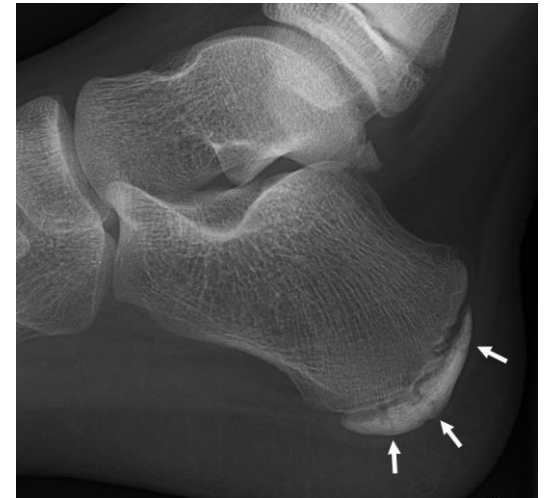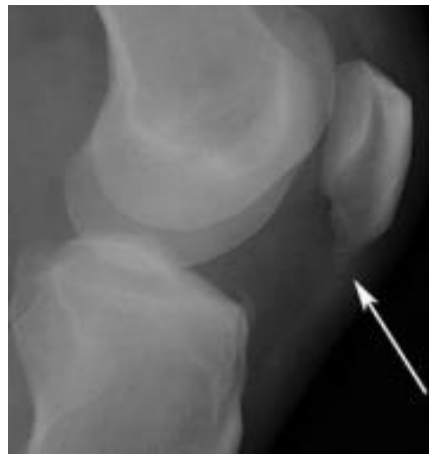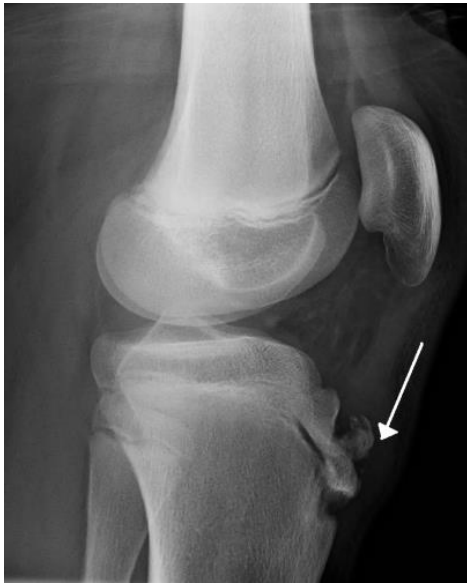Ossification center: place in a bone where ossification of cartilage begins

- primary: diaphysis
- secondary: epiphysis



WHAT IS APOPHYSITIS?

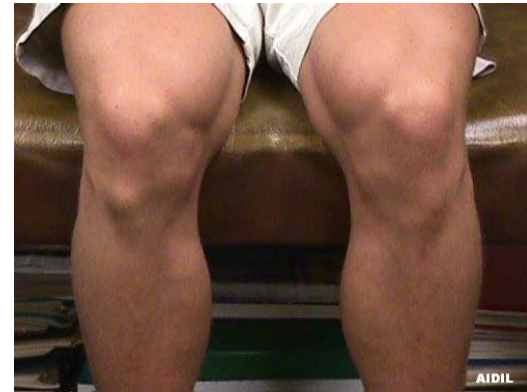- Tibial tubercle? → Osgood Schlatter's Disease
- Inferior patella? → Sinding-Larsen Johansson Disease
- Calcaneus? → Sever's Disease



APOPHYSITIS

Treatment: conservative

- activity modification
- RICE
- analgesics



...*rarely* need surgery, if the site fractures

Prognosis:

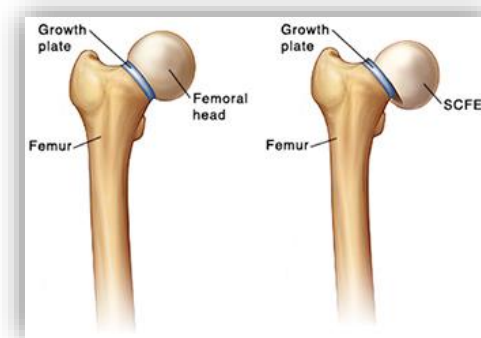
- symptoms can improve with treatment, rest
- complete resolution at *skeletal maturity*

SLIPPED CAPITOL FEMORAL EPIPHYSIS

⦿ aka SCFE

Background:

- *idiopathic* displacement, proximal femoral epiphysis
- occurs during rapid growth in adolescents
 - ages 10-16 (mean age of onset: 13)

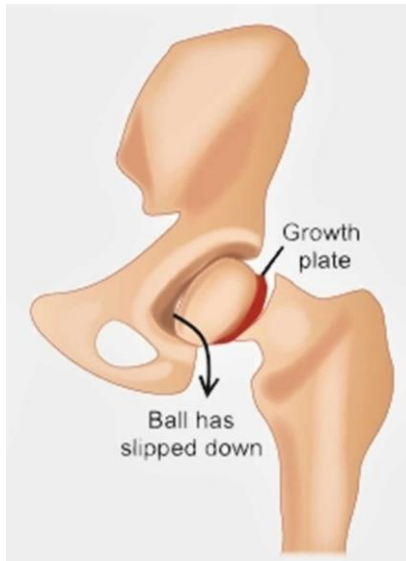


SLIPPED CAPITOL FEMORAL EPIPHYSIS

⦿ why does it displace?

- peri-chondral ring at femoral neck is too weak
- femoral head is held firmly in acetabulum...

...so femoral shaft slides superiorly





○ Risk Factors

- **Obesity** (increased pressure on growth plate)
- Males > Females
- Family history
- African Americans, Latinos,
- Endocrine disorders (hypogonadism, hypothyroid, growth hormone deficiency)

SCFE

○ Mild cases:

- atraumatic, insidious groin/hip pain
- worsens with activities
- may cause limp
- patient can c/o knee pain too

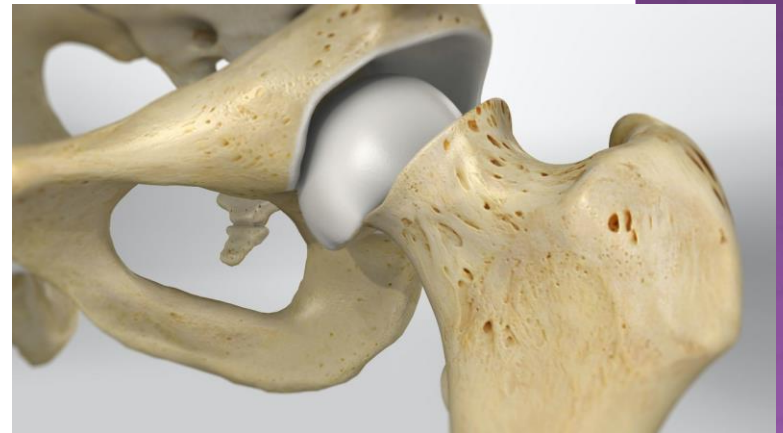
○ Severe cases:

- unable to walk
- leg appears shorter (more proximal) and externally rotated
- difficulty/pain with hip internal rotation and/or abduction

SCFE

Physical Exam

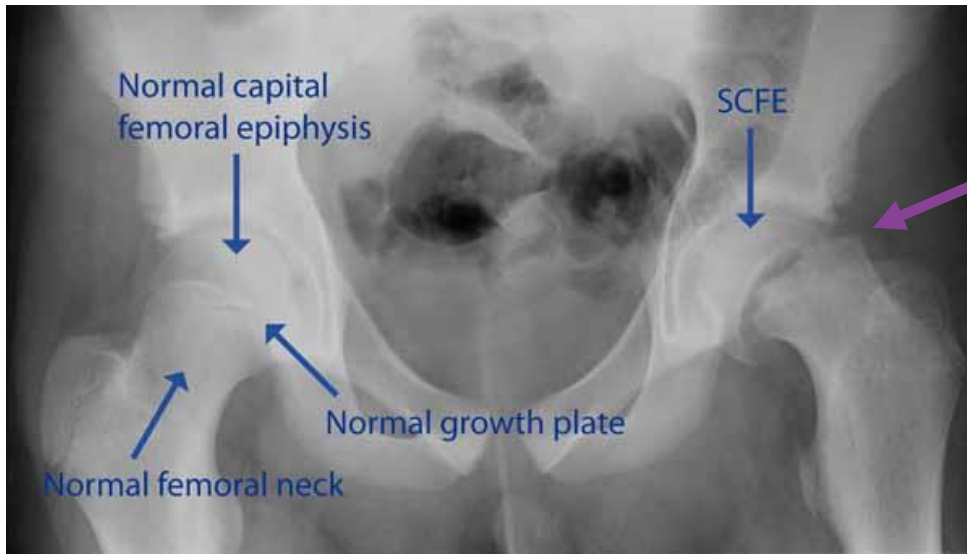
- limb shortened, externally rotated?
 - antalgic gait?
 - refusal to bear weight?
 - increased pain with passive hip internal rotation and/or abduction?
-
- ◉ 25-50% are bilateral
 - be sure to evaluate both hips



SCFE

Diagnosis:


- Pelvic X-rays
 - “ice cream falling from cone”
 - early sign: widening, irregularity of the physis
 - later: displacement



displacement

Acute Treatment:

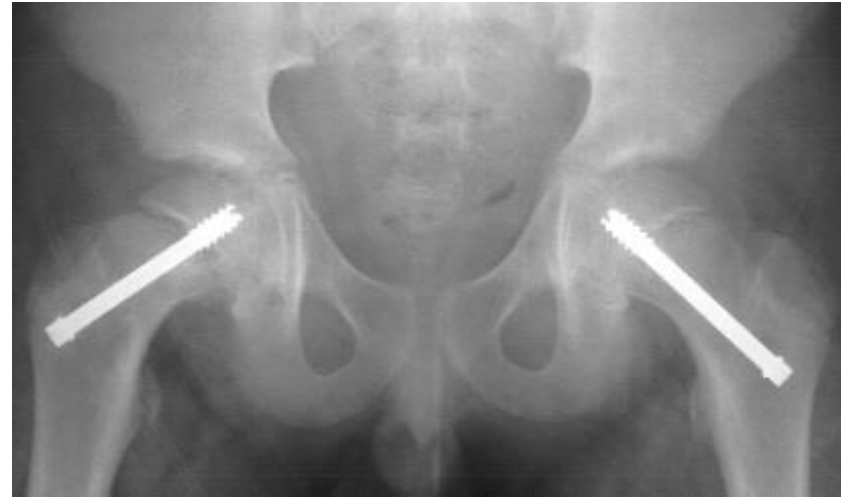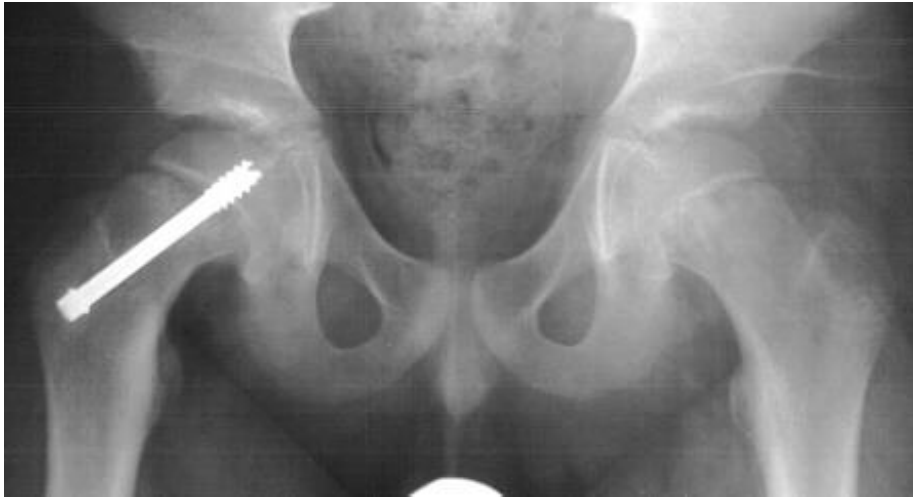- non-WB
- Pediatric Ortho referral



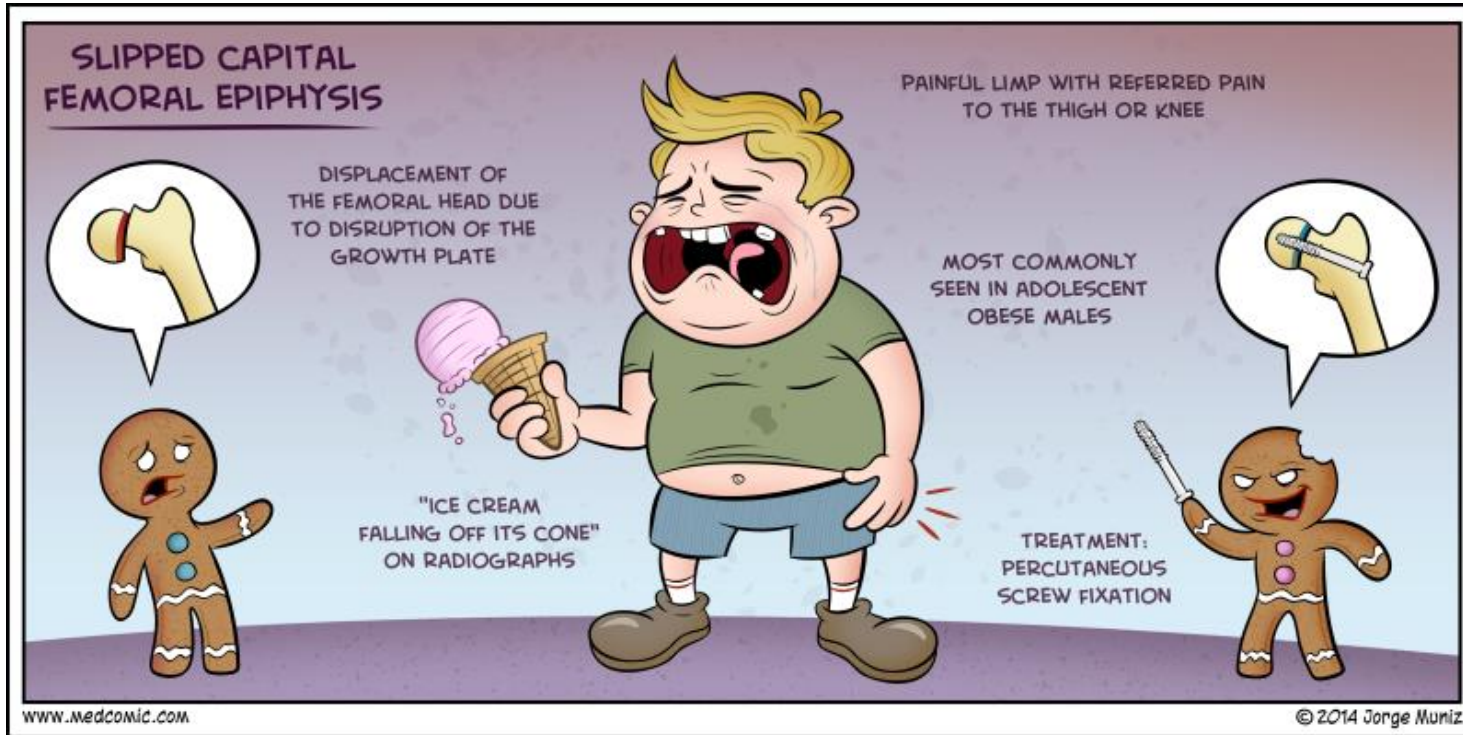
SCFE

Definitive Treatment:

- sometimes: period of minimal weight bearing, bed rest
- most often: surgical pinning to stabilize femoral head



**sometimes prophylactic pinning of contralateral hip before it also slips



LEGG-CALVE-PERTHES DISEASE

Incidence: affects 1 in 10,000 children

Demographics

- ◉ Can affect ages 2-15. Most often ages 4-8
- ◉ Male to female ratio is 5:1

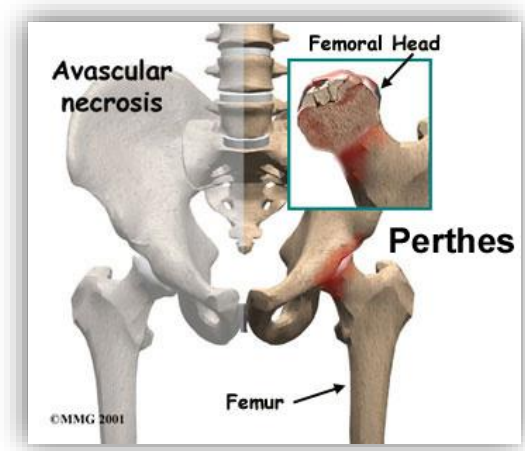
Risk Factors

- ◉ Family history
- ◉ low birth weight
- ◉ Hx of hip dysplasia
- ◉ Second-hand smoke

LEGG-CALVE-PERTHES DISEASE

Pathophysiology/Etiology


- Avascular necrosis of the femoral head
- Idiopathic...up to 50-75% have coagulopathy
 - Possible association with Protein S & protein C deficiency



LEGG-CALVE-PERTHES DISEASE

Symptoms

- ◉ Insidious onset
- ◉ May cause painless limp
- ◉ Intermittent pain in knee, groin, thigh, or hip



LEGG-CALVE-PERTHES DISEASE

Physical Exam

- ◉ Antalgic gait
- ◉ Decreased hip ROM (especially internal rotation & abduction)
- ◉ Leg length discrepancy is a late finding

Often missed diagnosis

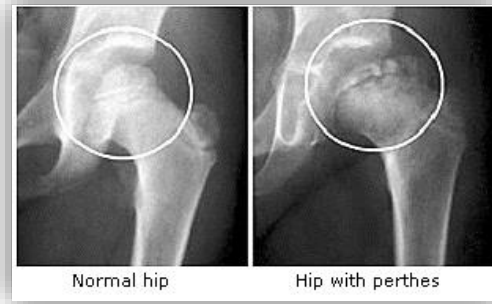
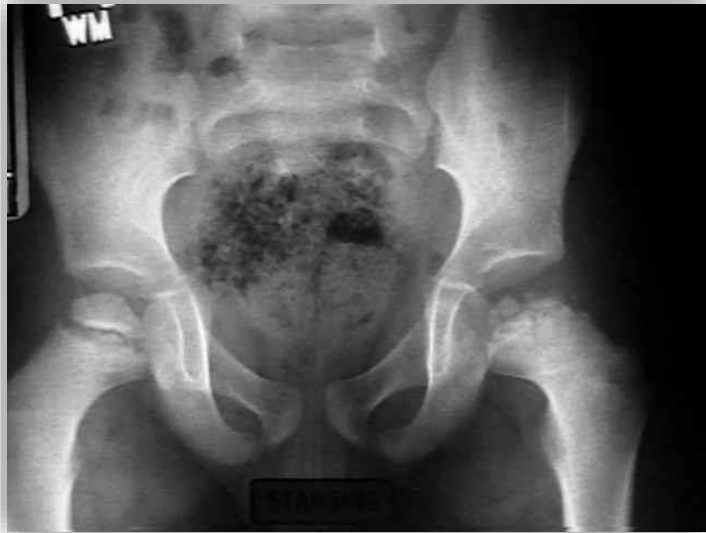- ◉ Litigation
- ◉ Dismissed as “growing pains”



LEGG-CALVE-PERTHES DISEASE

Imaging

- X-rays: AP of pelvis & 'frog leg' laterals



MRI

- More sensitive - picks up earlier disease!

LEGG-CALVE-PERTHES DISEASE

Acute Treatment:

- ◉ Symptom Management
 - NSAIDS, traction therapy, crutches
- ◉ Restore ROM
 - therapeutic exercises
- ◉ Pediatric Ortho referral

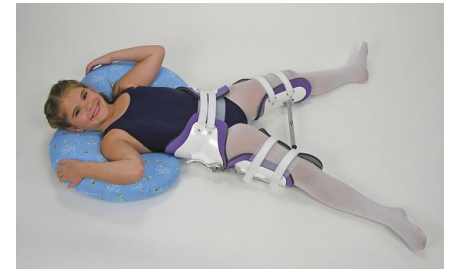

LEGG-CALVE-PERTHES DISEASE

Definitive Treatment: depends on age, mostly conservative

- Non-operative (children <8 years old):
 - activity restriction (non-WB)
 - therapeutic exercises (especially ROM)
 - *sometimes* abduction orthosis (controversial)

- Operative (children >8 years old):
 - femoral and/or pelvic osteotomies



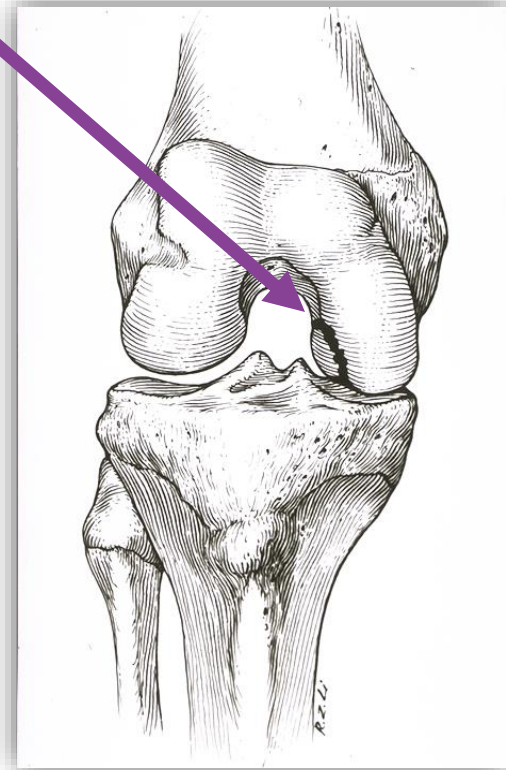
Prognosis: the younger treatment begins, the better

COMPARISON

Slipped Capital Femoral Epiphysis	Legg-Calve-Perthes Disease
Occurs between ages 10 - 16	Occurs between ages 4 - 8
Children tend to be overweight	Children tend to be short in stature
Displacement of femoral neck	Deformity (collapse) of femoral head
Treatment mostly operative	Treatment mostly conservative

OSTEOCHONDRITIS DISSECANS

- can occur in any joint
 - majority in the **knee** (lateral aspect of MFC)
- idiopathic
 - mostly in adolescents



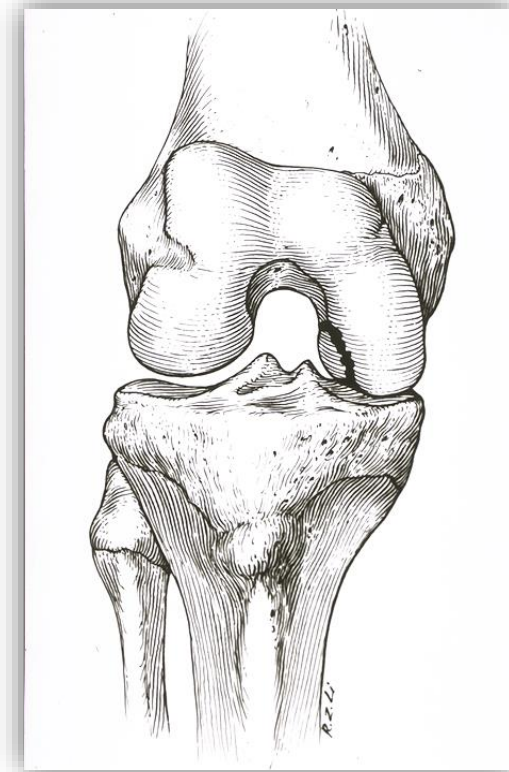
OSTEOCHONDRITIS DISSECANS

Subjective:

- no Hx of trauma
- knee pain
- inability to do activities/sports
- swelling (effusion?)

Physical Exam:

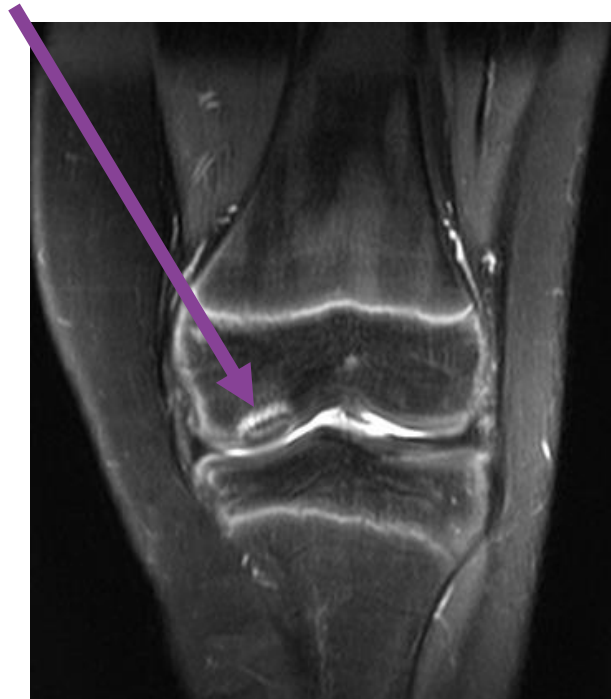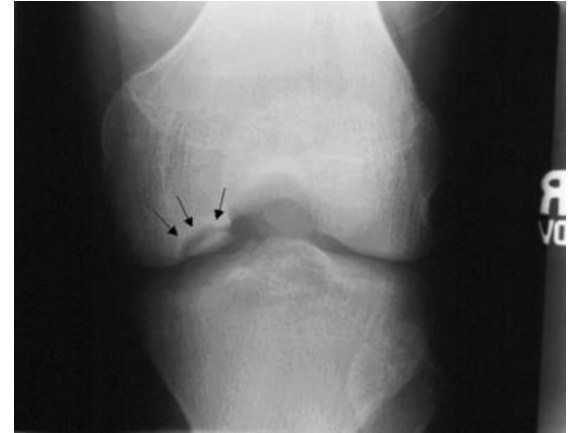- effusion
- mechanical Sx
- TTP on femoral condyle



OSTEOCHONDRITIS DISSECANS

Imaging:

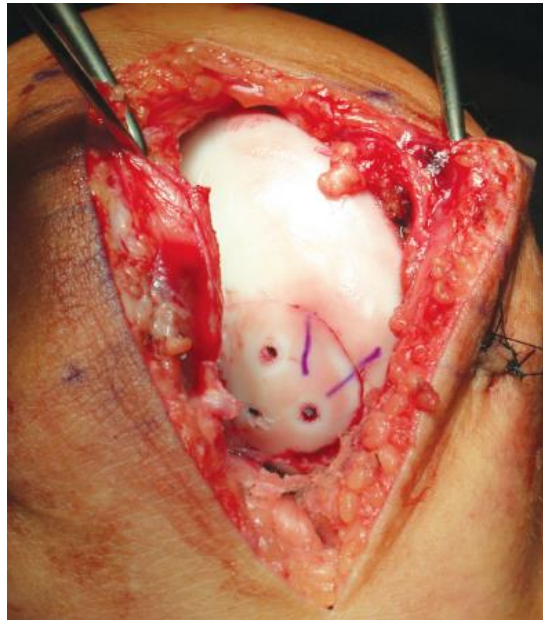
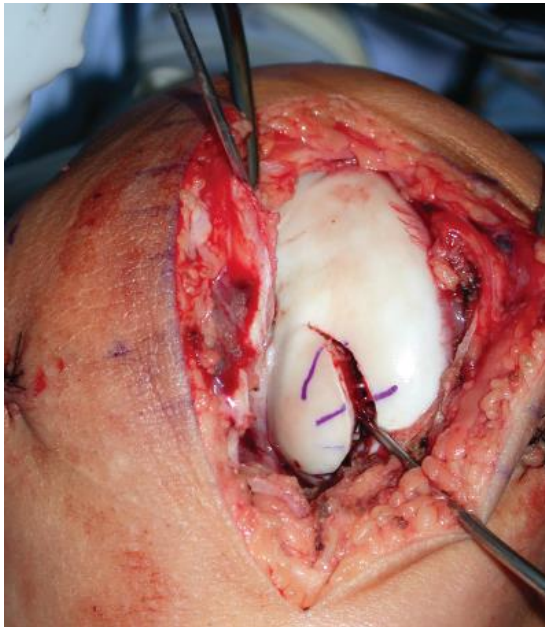
- X-rays: may see the defect if advanced
- MRI: much more sensitive
 - uncovers early/smaller lesions



OSTEOCHONDRITIS DISSECANS

Treatment:

- Non-operative: none
- Operative: absorbable pin(s)
 - if physes still open = better prognosis





PEDIATRIC FRACTURES

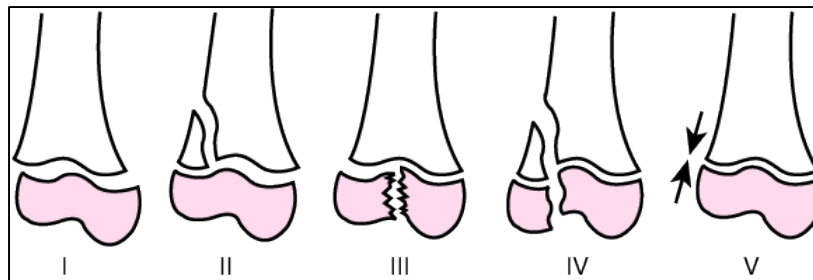
PEDIATRIC FRACTURES

○ Salter-Harris classification

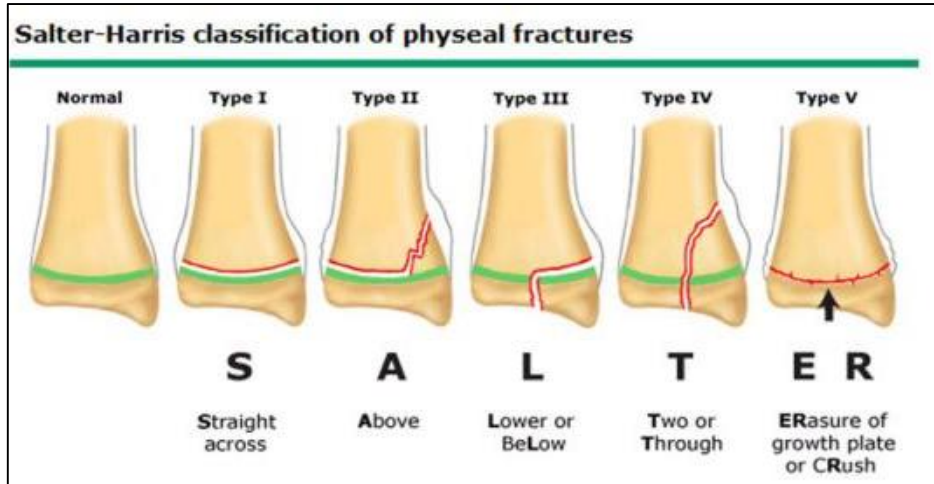
- epiphysis
- metaphysis
- physis aka growth plate aka epiphyseal plate

○ classification is important, determines...

- treatment
- prognosis
- complications



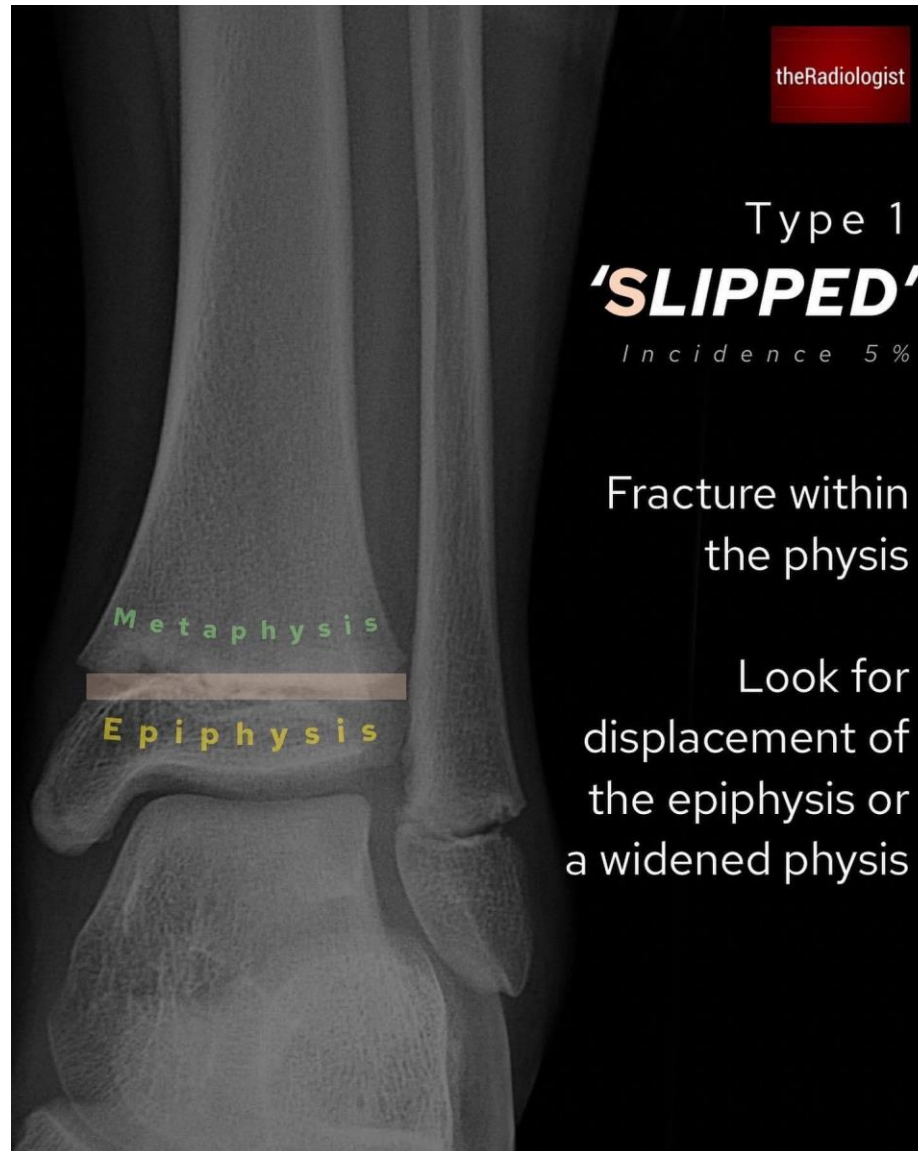
PEDIATRIC FRACTURES



Source: UpToDate

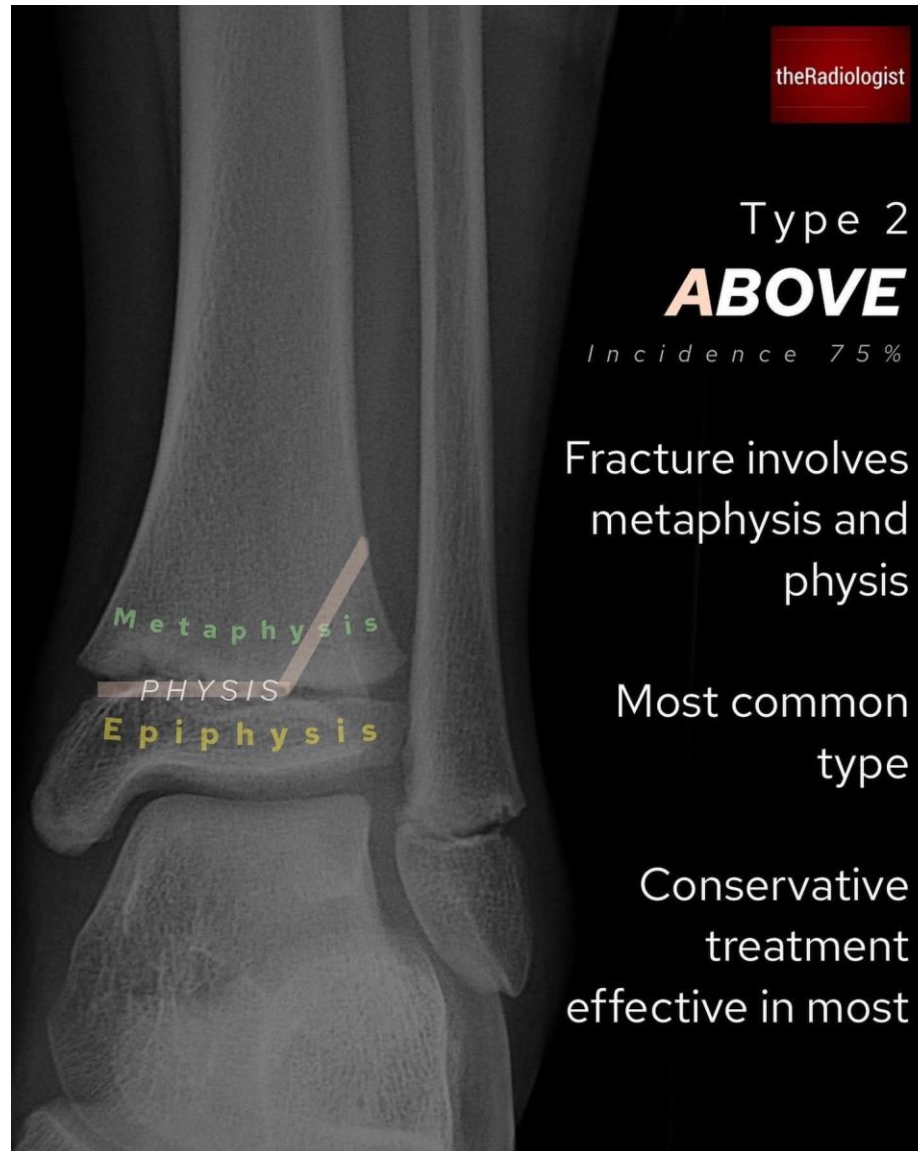
PEDIATRIC FRACTURES

- S - Slipped
- A - Above
- L - beLow
- T - Through
- (e)
- R - Rammed



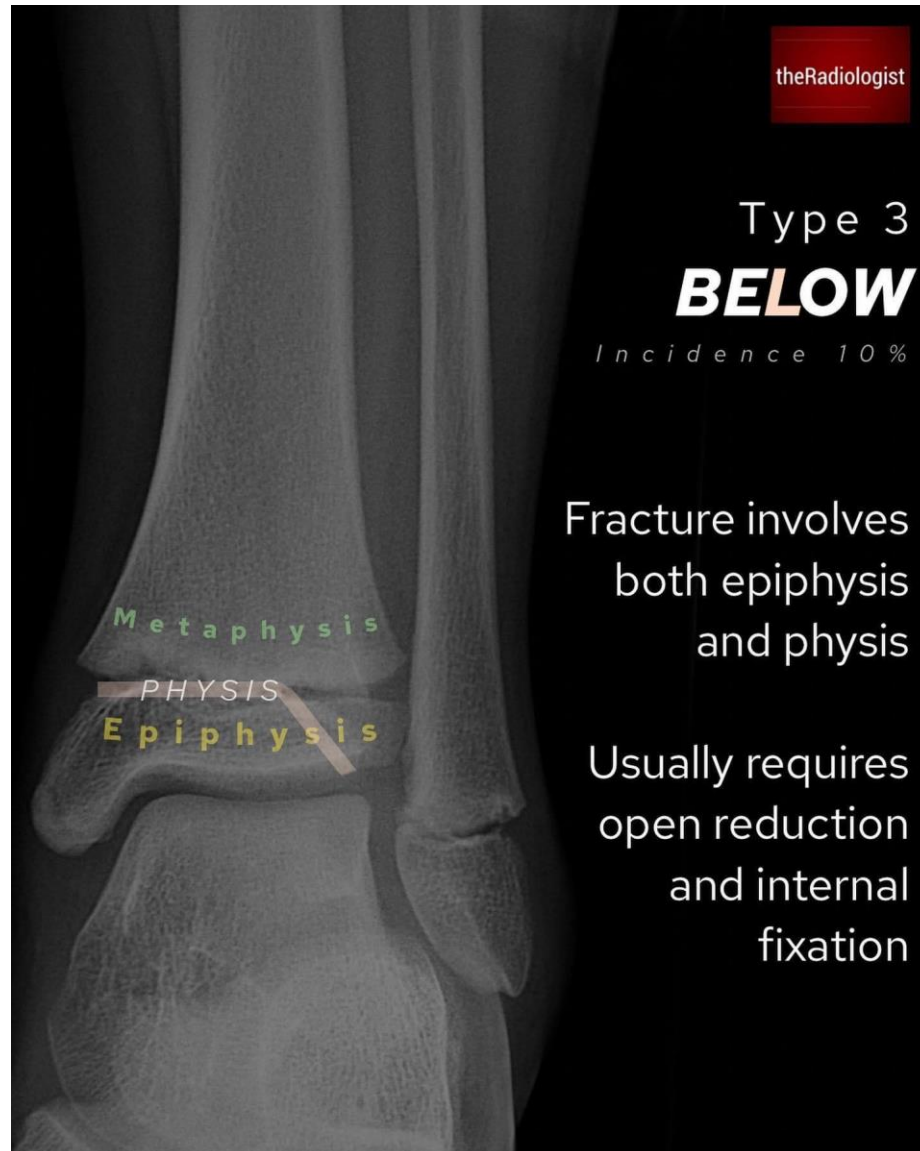
PEDIATRIC FRACTURES

- S - Slipped
- A - Above
- L - beLow
- T - Through
- (e)
- R - Rammed



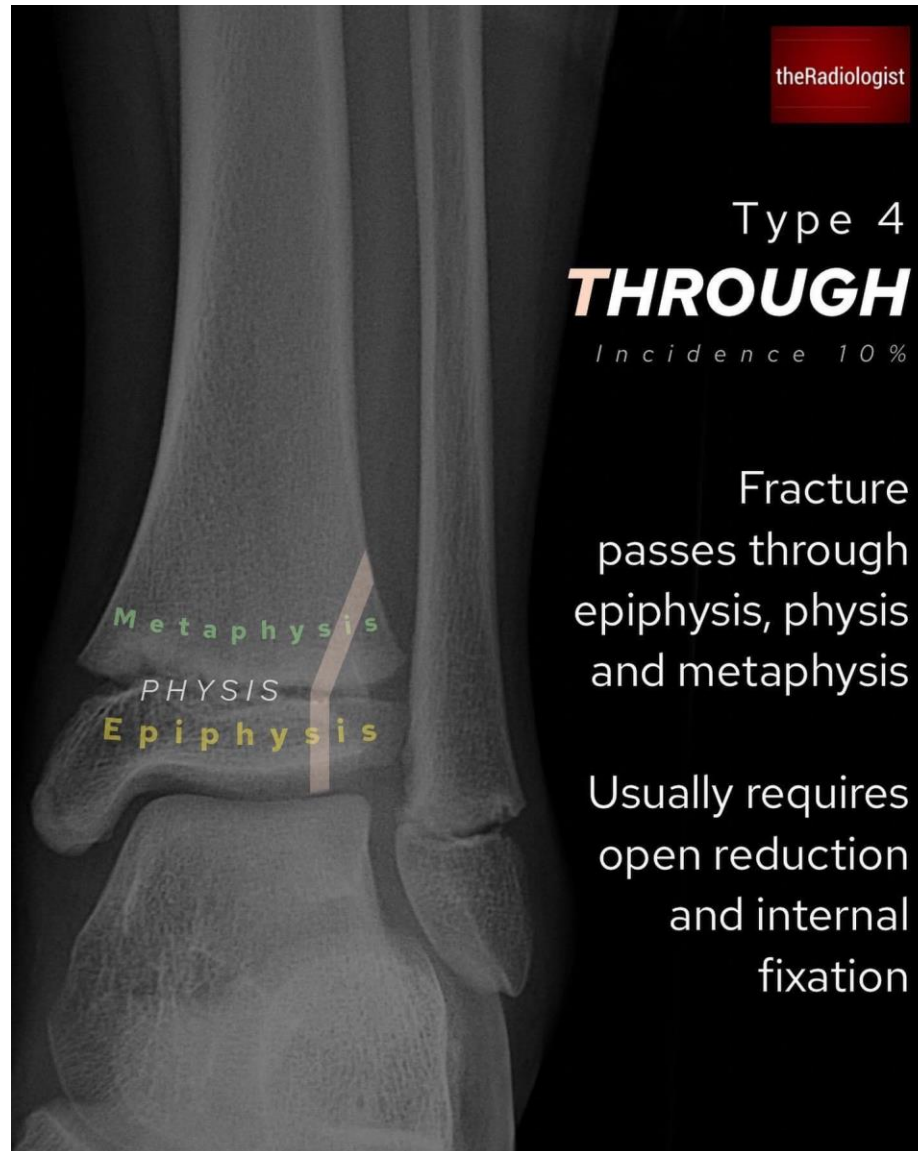
PEDIATRIC FRACTURES

- S - Slipped
- A - Above
- L - beLow
- T - Through
- (e)
- R - Rammed



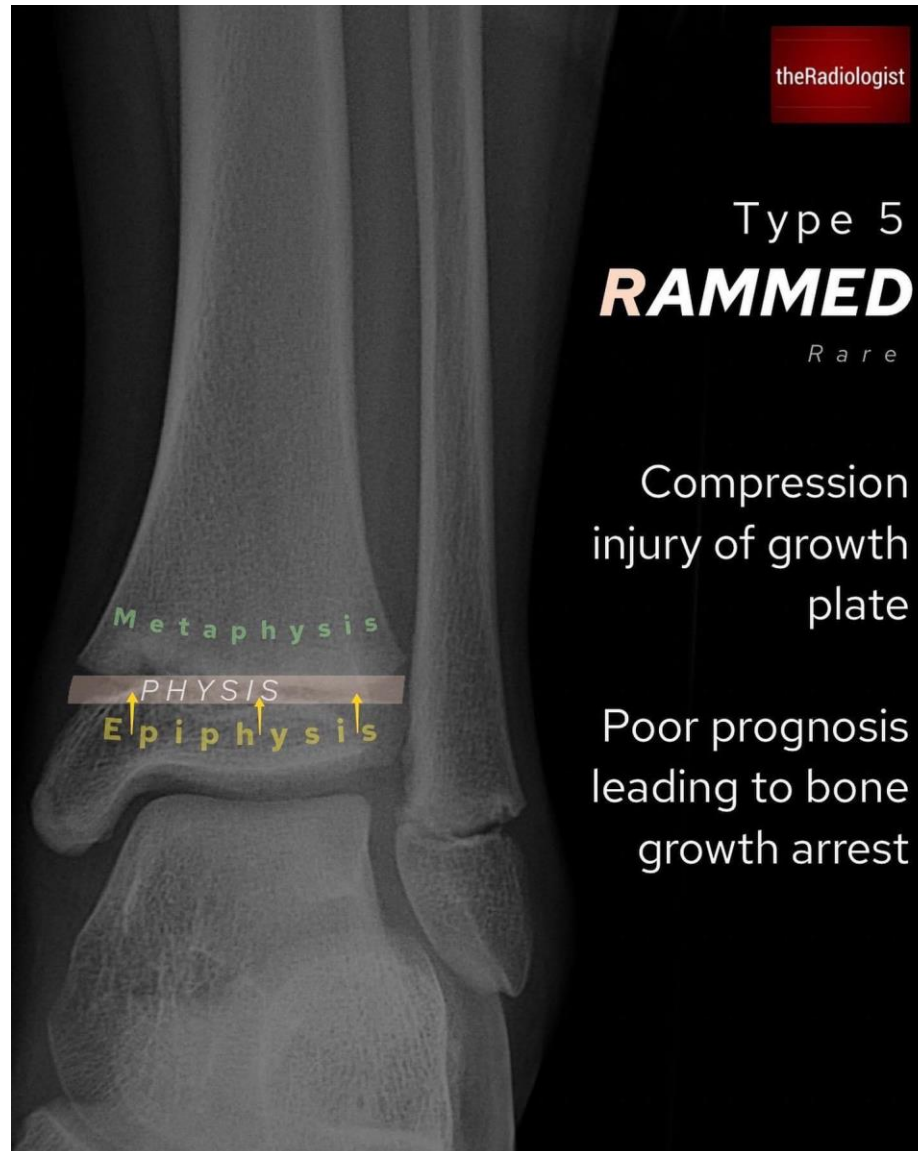
PEDIATRIC FRACTURES

- S - Slipped
- A - Above
- L - beLow
- T - ThrougH
- (e)
- R - Rammed

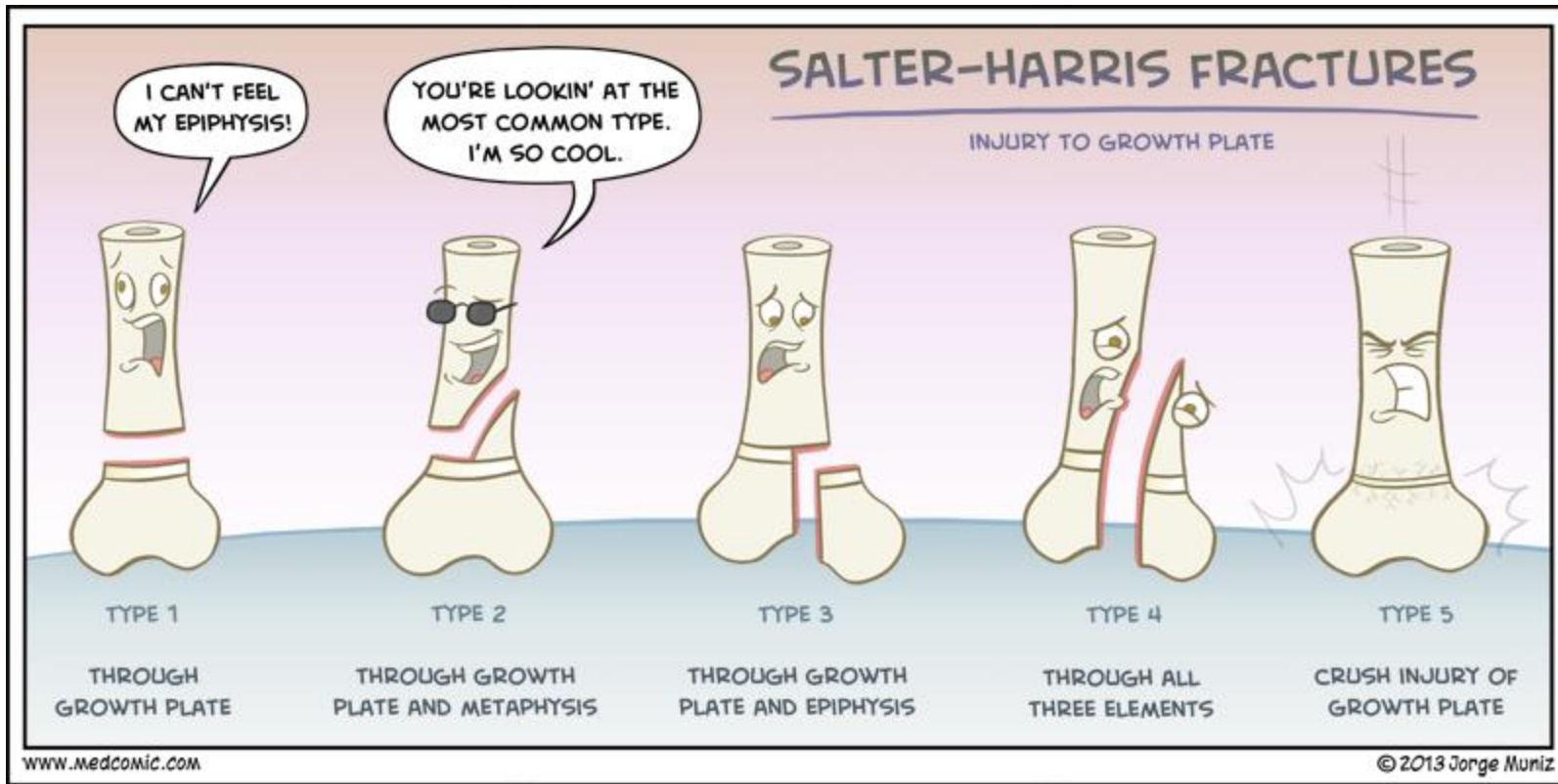


PEDIATRIC FRACTURES

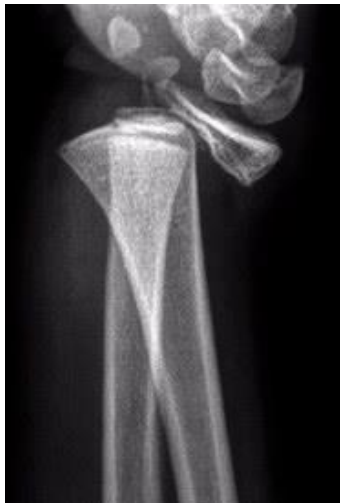- S - Slipped
- A - Above
- L - beLow
- T - Through
- (e)
- R - Rammed



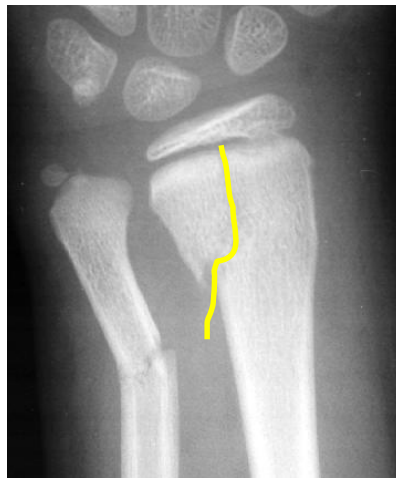PEDIATRIC FRACTURES



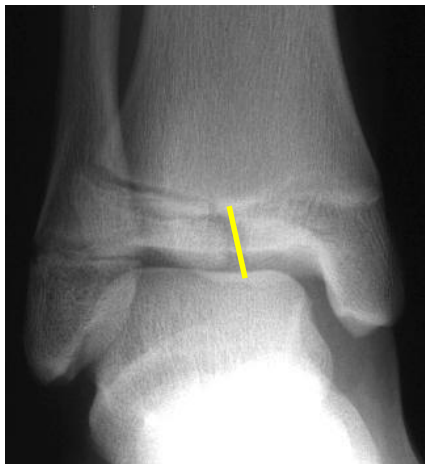PEDIATRIC FRACTURES



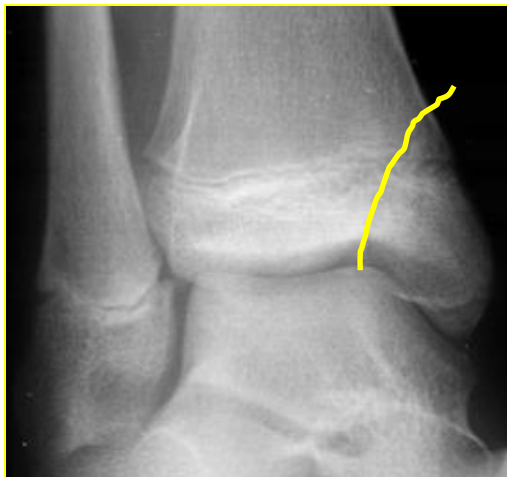TYPE 1



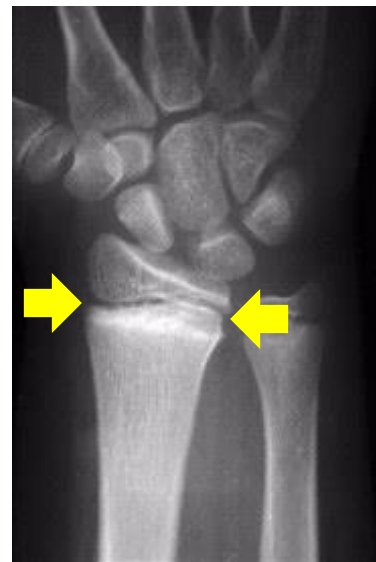TYPE 2



TYPE 3



TYPE 4



TYPE 5

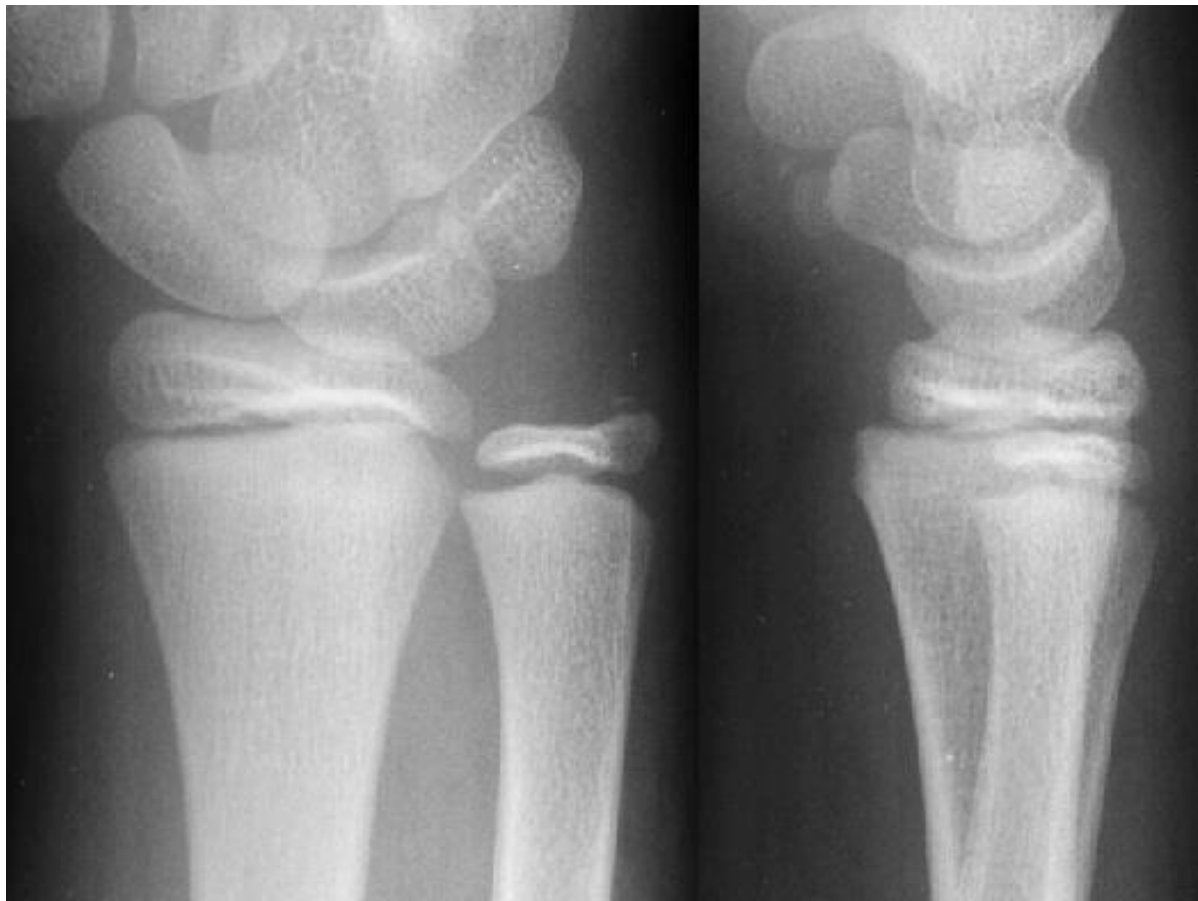PEDIATRIC FRACTURES

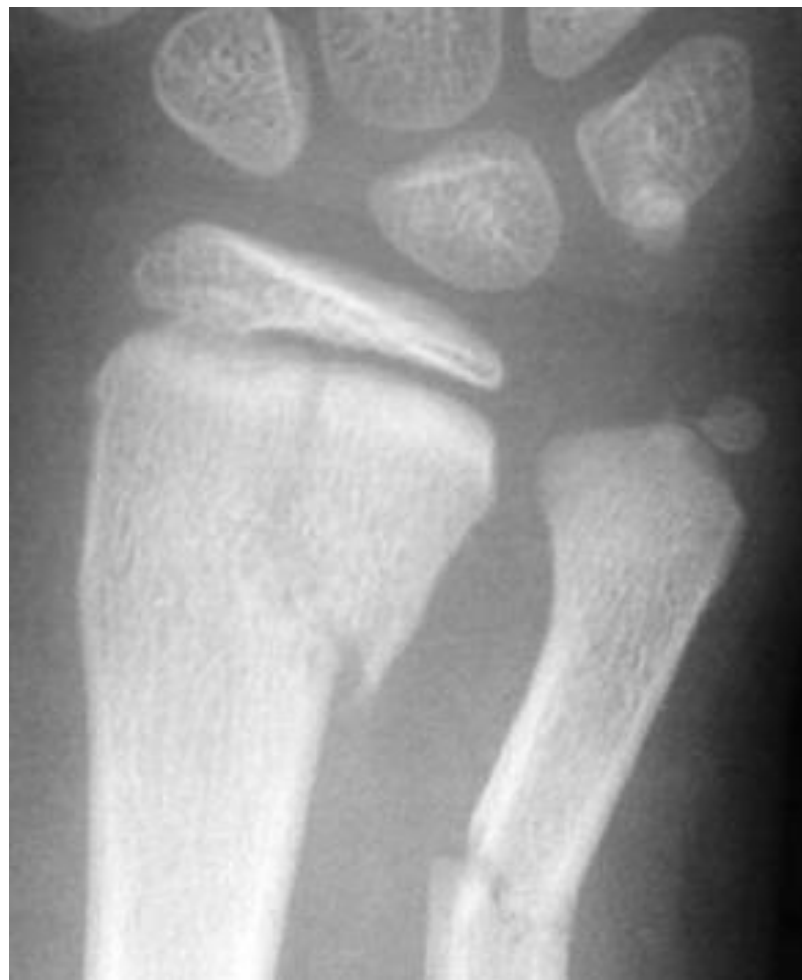Summary of Prognosis (Salter-Harris)

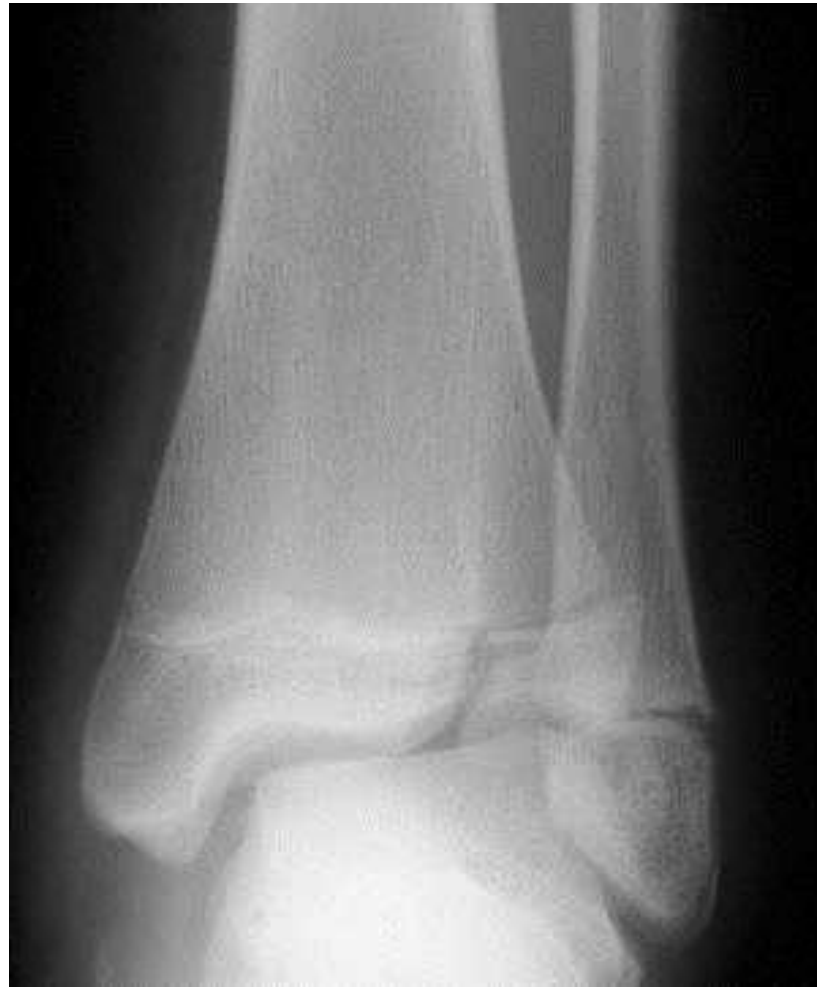- Type 1 - Good
- Type 2 - Good***
- Type 3 - Poor
- Type 4 - Poor
- Type 5 - Worst

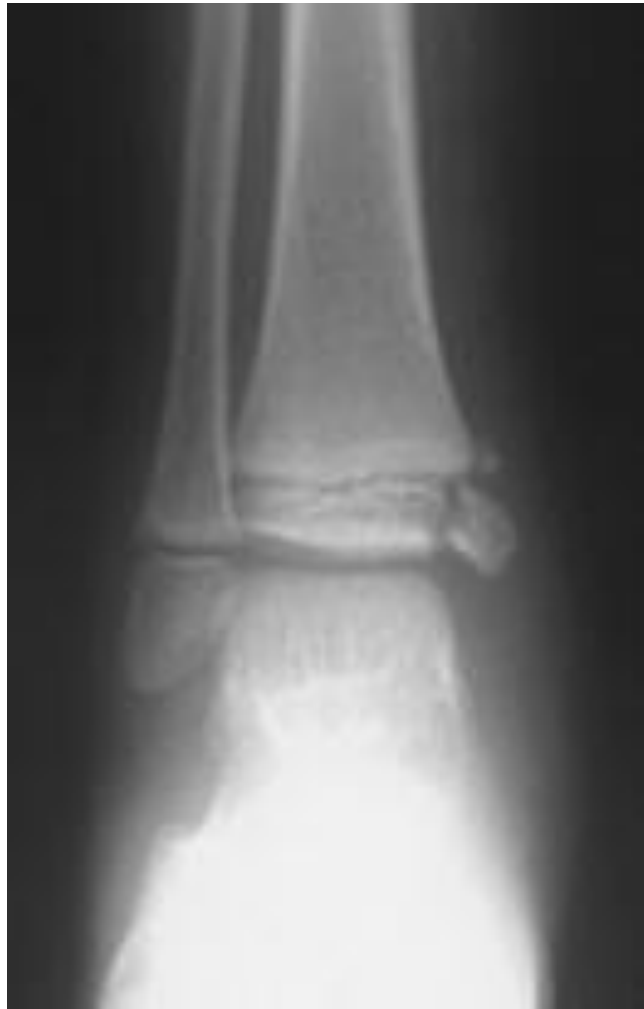

***the most common type of SH fracture



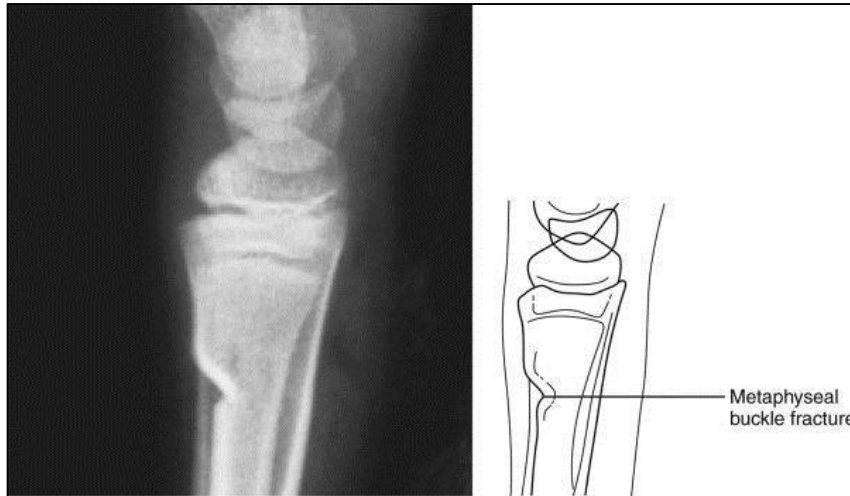






PEDIATRIC FRACTURES

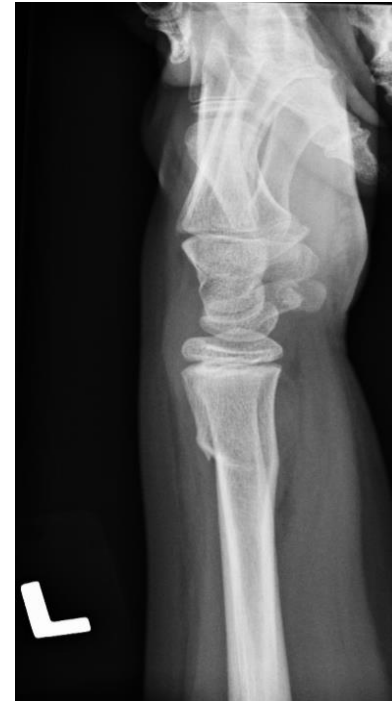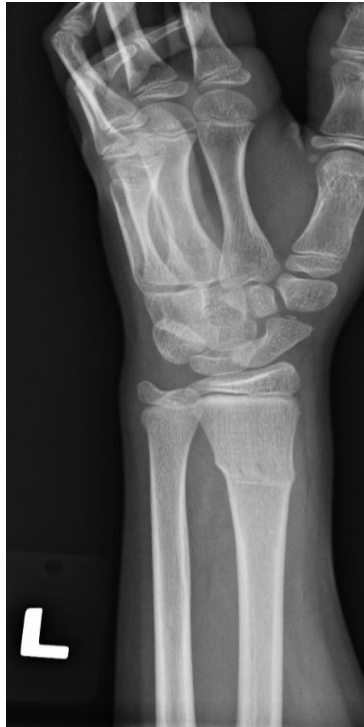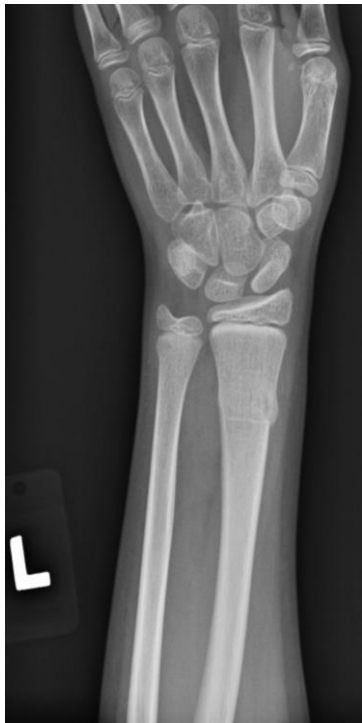- torus (buckle) fracture



an incomplete fracture...a bowing or bending deformation

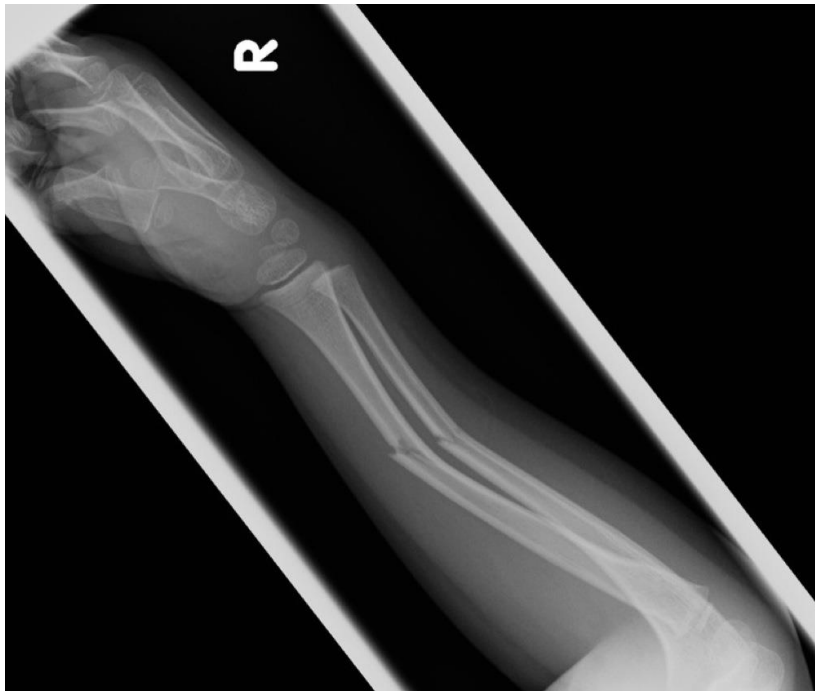PEDIATRIC FRACTURES

- torus (buckle) fracture



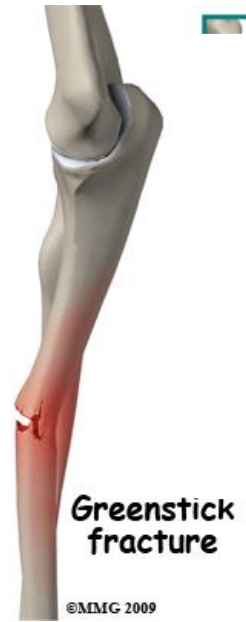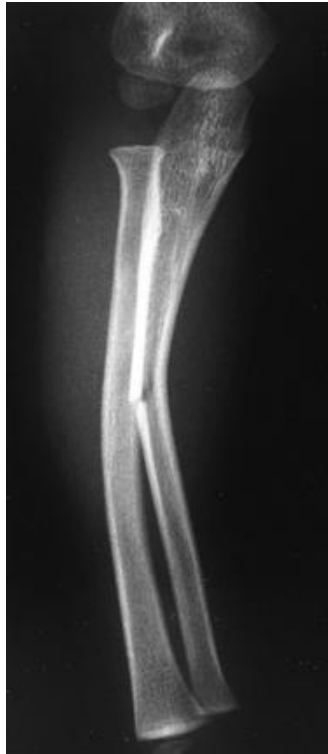PEDIATRIC FRACTURES

- “Greenstick” fracture



PEDIATRIC FRACTURES

- “Greenstick” fracture



PEDIATRIC FRACTURES

- ⊙ Common: limb fractures ≤ 16 yo
 - boys 3x more likely than girls
- ⊙ more common in the summer



PEDIATRIC FRACTURES

- weaker than adult bones
- bones more “plastic”
 - absorb more energy before breaking
 - incomplete fractures more common
 - fracture types not seen in adults



BOTH BONE FOREARM FRACTURE

Epidemiology

- one of the most common pediatric fractures
- approximately 40% of all peds fractures
- more common in males

Mechanism of injury (MOI)

- fall from height
- athletics
- playground injury

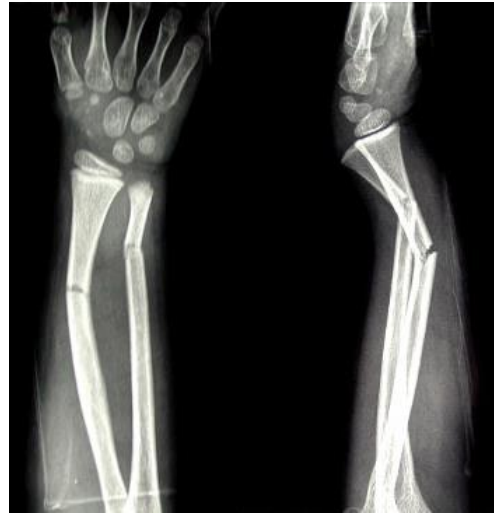BOTH BONE FOREARM FRACTURE

Symptoms

- forearm/wrist pain
- refusal to use arm

Physical Exam

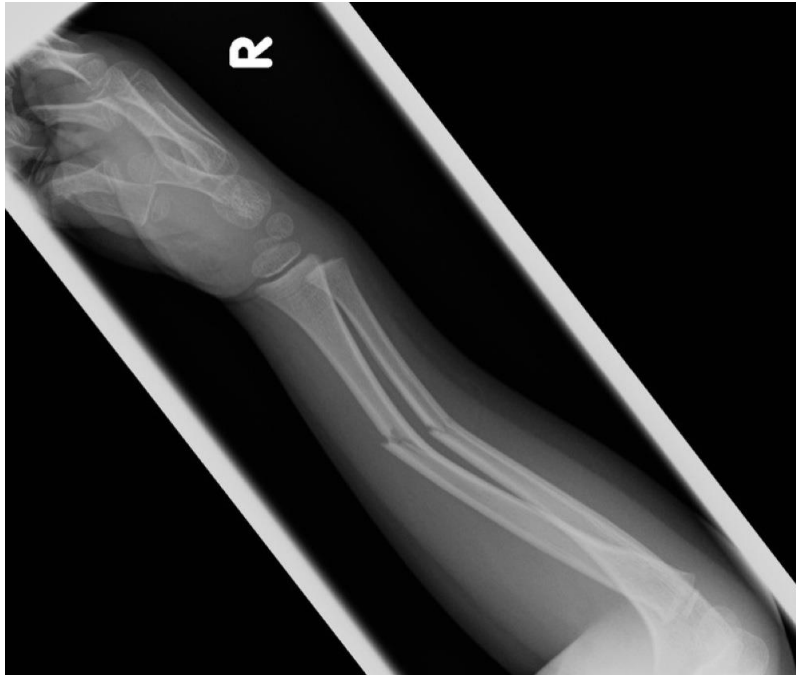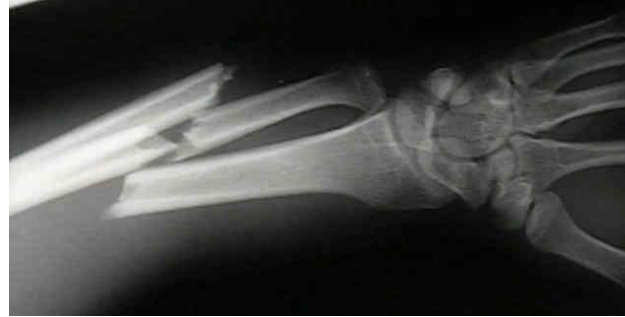- deformity
- swelling
- ecchymosis



BOTH BONE FOREARM FRACTURE

Imaging

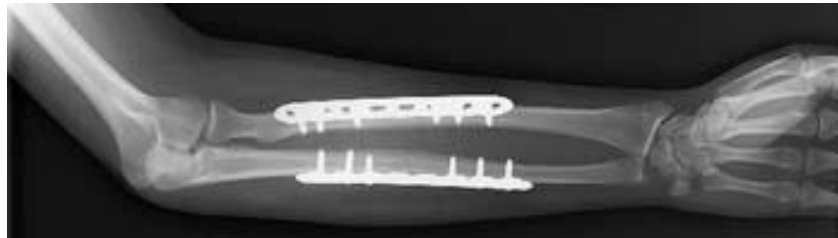- X-rays



BOTH BONE FOREARM FRACTURE

Treatment

- ⦿ Non-operative
 - closed reduction, casting
- ⦿ Operative
 - when alignment is unacceptable following a closed reduction
 - highly displaced or comminuted

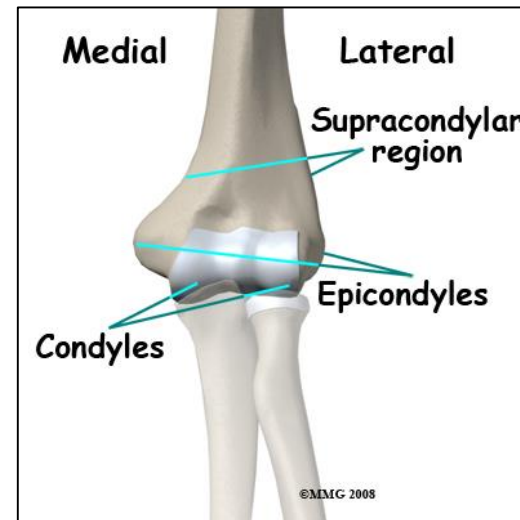


SUPRACONDYLAR HUMERUS FRACTURE

Epidemiology

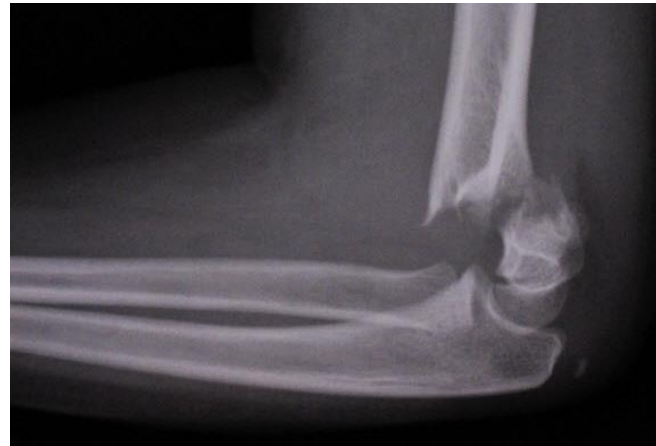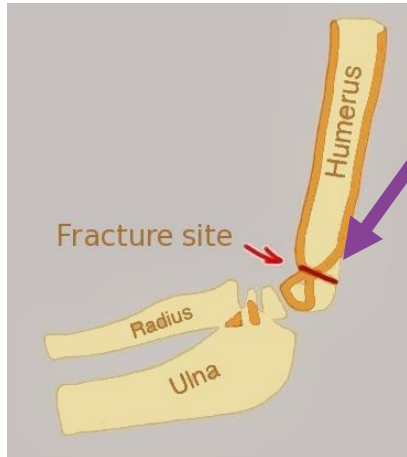
- most common in age 5-7 years
- male = female

Mechanism of injury: FOOSH



SUPRACONDYLAR HUMERUS FRACTURE

- ◉ developmentally weak point in distal humerus



SUPRACONDYLAR HUMERUS FRACTURE

Symptoms

- ⦿ pain
- ⦿ refusal to move elbow

Physical Exam

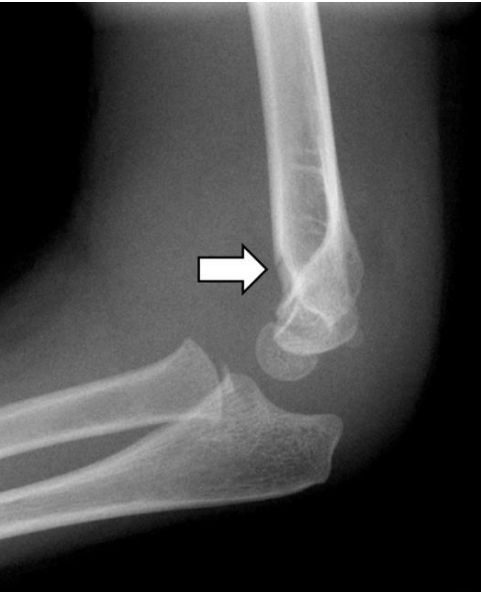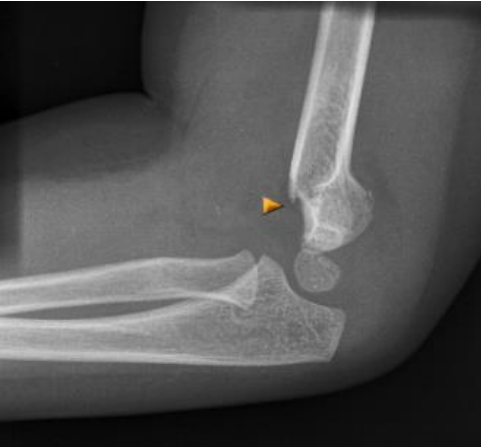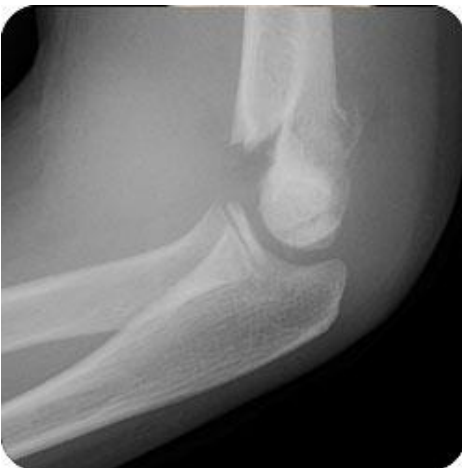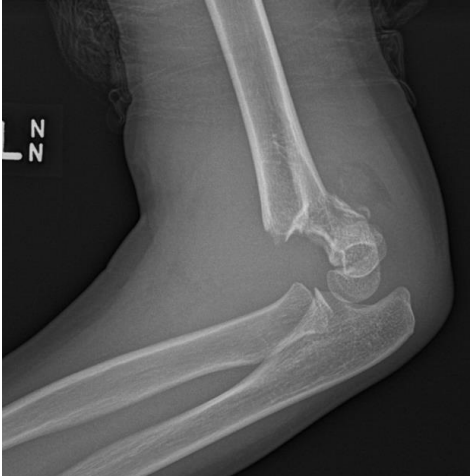- ⦿ gross deformity, swelling, ecchymosis
- ⦿ limited active ROM
- ⦿ assess pulses
- ⦿ neuro: evaluate median & radial nerve function

SUPRACONDYLAR HUMERUS FRACTURE

Imaging

- X-rays

...may be obvious...

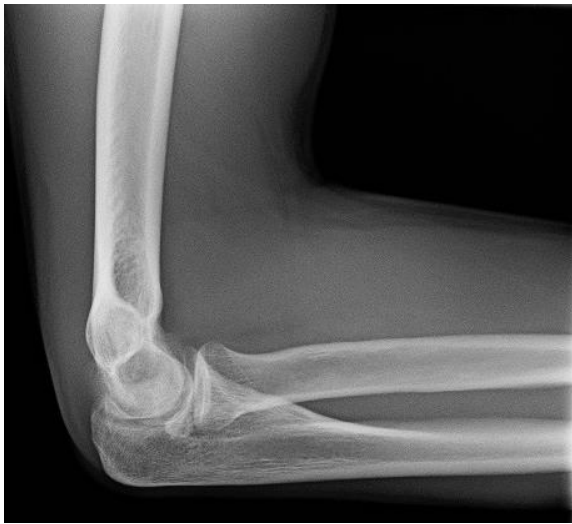

SUPRACONDYLAR HUMERUS FRACTURE

Imaging

- X-rays

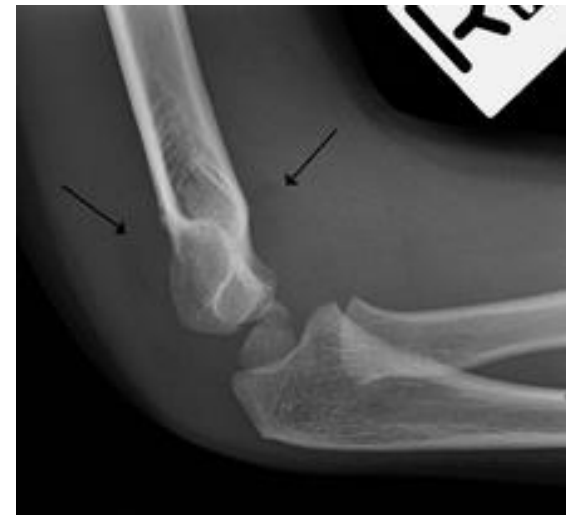...may NOT be as obvious...



Normal elbow X-ray

- anterior fat pad is visible
- posterior fat pad is NOT visible

“sail sign” or “fat pad sign”

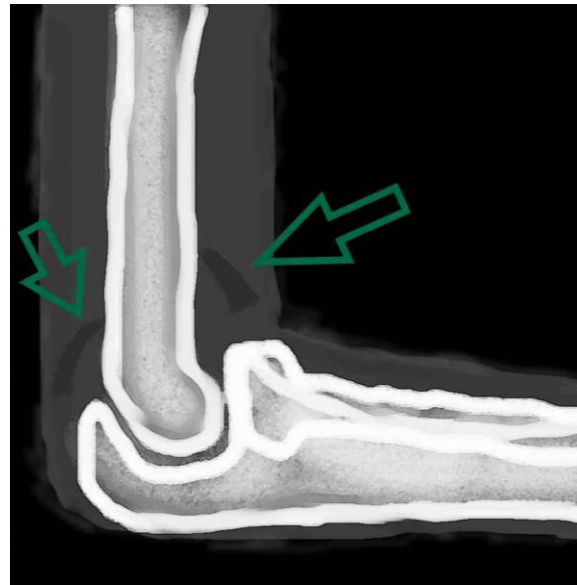
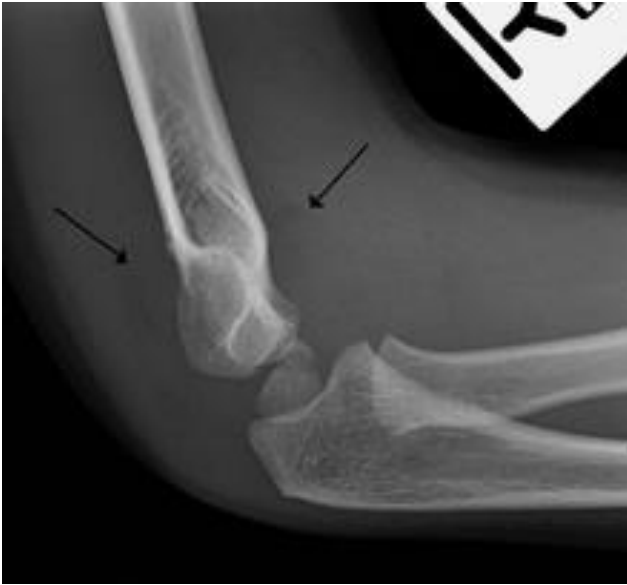

Occult (hidden) fracture

- anterior fat pad displaced forward
- posterior fat pad is visible

SUPRACONDYLAR HUMERUS FRACTURE

“sail sign” or “fat pad sign”



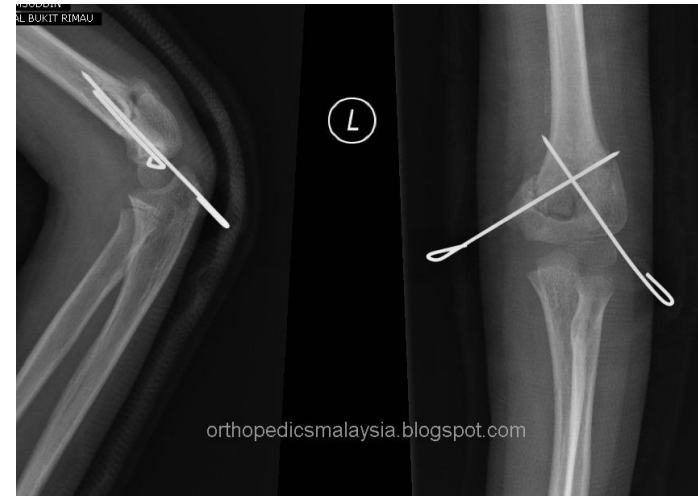
Occult (hidden) fracture

- ⦿ anterior fat pad displaced forward
- ⦿ posterior fat pad is visible

SUPRACONDYLAR HUMERUS FRACTURE

Treatment

- Non-operative
 - few managed conservatively (if non-displaced)
 - long arm casting with $<90^\circ$ of elbow flexion
- Operative
 - often necessary
 - closed reduction, percutaneous pinning



TIBIAL SHAFT FRACTURE

Incidence: 15% of all pediatric fractures

Demographics

- average age: 8 years
- males > females



Mechanism of Injury

- MVCs
- direct blow
- in toddlers: twist or fall
 - torsion forces cause spiral/oblique fracture pattern
 - aka “Toddlers Fracture”

TIBIAL SHAFT FRACTURE

Symptoms

- pain
- limping, refusal to bear weight

Physical Exam

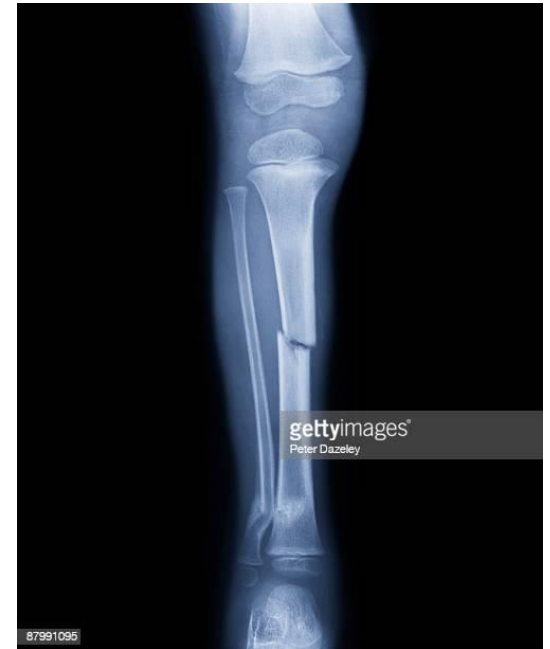- deformity, swelling, ecchymosis
- tender to palpation
- pain with ankle motion
- have high suspicion for compartment syndrome



TIBIAL SHAFT FRACTURE

Imaging

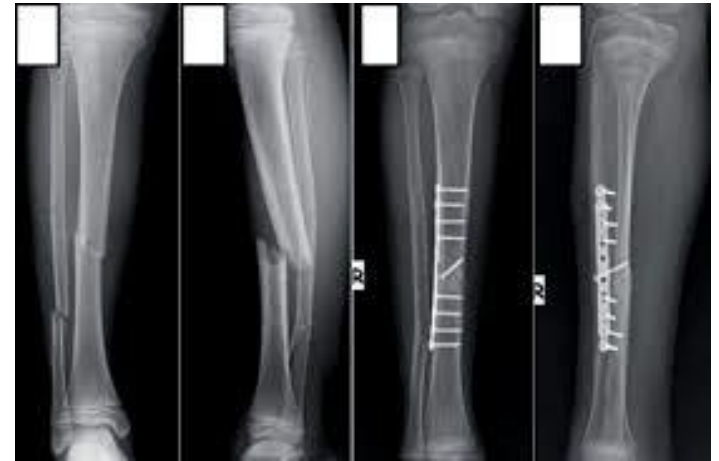- X-rays: AP & lateral views of tibia/fibula
 - Toddlers fracture may be missed
- CT: concern for missed fracture
 - also for possible intra-articular involvement



TIBIAL SHAFT FRACTURE

Treatment

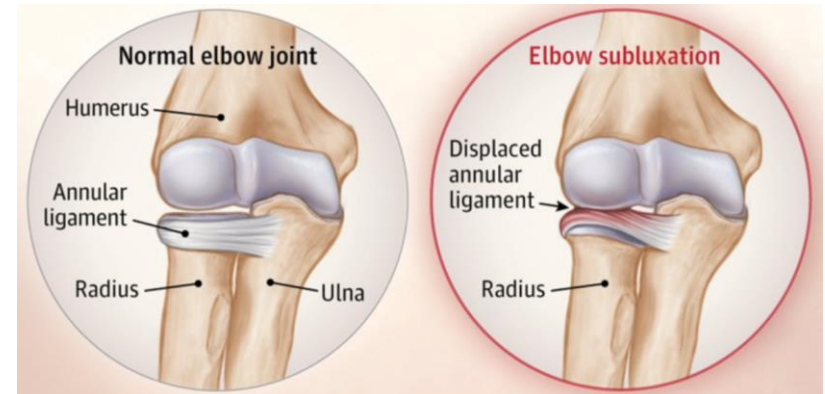
- Non-operative: long leg casting
 - almost all Toddlers fractures
 - greenstick fractures
 - may need closed reduction first
- Operative: many options!
 - intramedullary nail (flexible or rigid)
 - percutaneous pinning
 - plate fixation
 - external fixation



NURSEMAIDS ELBOW

Etiology

- subluxation of radial head from the annular ligament
- sudden longitudinal traction applied to hand with elbow extended



Demographics

- mostly in children ages 1-4
- average age: 28 months
- rare in kids >5 years old

NURSEMAIDS ELBOW

History/Symptoms

- child refuses to use affected arm
- holds elbow in flexion, slight pronation
- often no direct trauma

Physical Exam

- tender to palpation, lateral elbow
- pain with attempted supination



NURSEMAIDS ELBOW

Imaging Decisions!

- Obtain X-rays if child with direct trauma or fall
- X-rays not required when “classic” presentation
 - history of traction injury
 - child is <5 years old
 - consistent exam

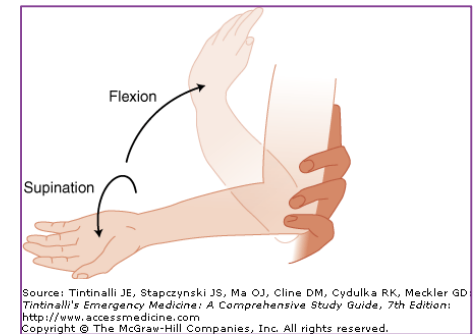
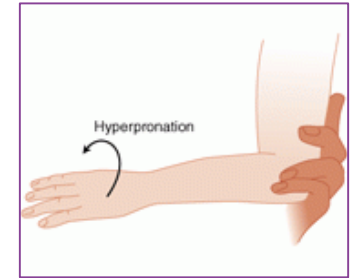
NURSEMAIDS ELBOW

Treatment

- Non-operative: vast majority of cases

- Reduction methods:

1. Hyper-pronation
2. Supinate forearm, then flex elbow



Source: Tintinalli JE, Stapczynski JS, Ma OJ, Cline DM, Cydulka RK, Meckler GD.
Tintinalli's Emergency Medicine: A Comprehensive Study Guide, 7th Edition.
<http://www.accessmedicine.com>
Copyright © The McGraw-Hill Companies, Inc. All rights reserved.

- Operative: very rare

- chronic cases, or subluxations that cannot be reduced

CHILD ABUSE

Red Flags: *parent* behavior

- delay in seeking care
- vague history
- EtOH/substance abuse
- blames it on the ex-spouse



CHILD ABUSE

Red Flags: *child* behavior

- overly passive
- overly aggressive
- multiple fractures in different stages



CHILD ABUSE

Legal Considerations

- Child Protective Services (CPS)
- most states mandate reporting
- immune from liability if report
 - even if no actual abuse occurred



POST-TEST QUESTION #1

A 5-year old boy is being seen for a limp. The parents note that the boy has been gradually refusing to run. There has been no rash or fever. He exhibits an antalgic gait and has limited hip ROM. X-rays were normal. MRI shows signal changes in right femoral head consistent with decreased perfusion. What is the most likely diagnosis?

- A. Slipped capital femoral epiphysis
- B. Osteomyelitis
- C. Transient tenosynovitis
- D. Legg-Calve-Perthes disease

POST-TEST QUESTION #1

A 5-year old boy is being seen for a limp. The parents note that the boy has been gradually refusing to run. There has been no rash or fever. He exhibits an antalgic gait and has limited hip ROM. X-rays were normal. MRI shows signal changes in right femoral head consistent with decreased perfusion. What is the most likely diagnosis?

- A. Slipped capital femoral epiphysis
- B. Osteomyelitis
- C. Transient tenosynovitis
- D. Legg-Calve-Perthes disease

POST-TEST QUESTION #2

A 4-year old girl refuses to use her right arm after her Dad tugged on her arm to keep her from falling as they stepped off from a curb. She is in no distress, but is holding her arm against her chest in pronation and slight elbow flexion. What is the next best step?

- A. Hyper-pronate her forearm while applying pressure to the radial head
- B. Obtain X-rays of the elbow & forearm
- C. Place the patient in a splint and refer to Ortho
- D. Using fluoroscopy, perform arthrocentesis of elbow

POST-TEST QUESTION #2

A 4-year old girl refuses to use her right arm after her Dad tugged on her arm to keep her from falling as they stepped off from a curb. She is in no distress, but is holding her arm against her chest in pronation and slight elbow flexion. What is the next best step?

- A. Hyper-pronate her forearm while applying pressure to the radial head
- B. Obtain X-rays of the elbow & forearm
- C. Place the patient in a splint and refer to Ortho
- D. Using fluoroscopy, perform arthrocentesis of elbow

POST-TEST QUESTION #3

A 13-year old boy presents with gradually worsening right knee pain. He is on the soccer team at school and notes his pain is worse after practice. His knee is tender to palpation over his tibial tuberosity. There is no joint effusion nor ligamentous laxity. His pain is worst with resisted knee extension. What is the next best step?

- A. Corticosteroid injection at patellar tendon insertion
- B. Place him in a knee immobilizer and crutches
- C. Recommend NSAIDS and activity as tolerated
- D. Refer to Ortho for surgical intervention

POST-TEST QUESTION #3

A 13-year old boy presents with gradually worsening right knee pain. He is on the soccer team at school and notes his pain is worse after practice. His knee is tender to palpation over his tibial tuberosity. There is no joint effusion nor ligamentous laxity. His pain is worst with resisted knee extension. What is the next best step?

- A. Corticosteroid injection at patellar tendon insertion
- B. Place him in a knee immobilizer and crutches
- C. Recommend NSAIDS and activity as tolerated
- D. Refer to Ortho for surgical intervention

CITATIONS

1. Kienstra, AJ, Macias, CG. Evaluation and management of slipped capital femoral epiphysis (SCFE). In: UpToDate, Phillips, WA, Singer, JI, Wiley, JF. Waltham, MA, 2022.
2. Nigrovic, PA. Approach to hip pain in childhood. In: UpToDate, Drutz, JE, Phillips, WA, Li, SC, Torchia, MM. Waltham, MA, 2022.
3. Moore, BR, Bothner, J. Radial head subluxation (pulled elbow): Evaluation and management. In: UpToDate, Stack, AM, Wiley, JF. Waltham, MA, 2022.
4. Ryan, LM. Evaluation and management of supracondylar fractures in children. In: UpToDate, Boutis, K, Wiley, JF. Waltham, MA, 2022.
5. Kienstra, Aj, Macias, CG. Osgood-Schlatter disease (tibial tuberosity avulsion). In: UpToDate, Phillips, WA, Singer, JI, Wiley, JF. Waltham, MA, 2022.
6. Chapman, J, Cohen, J. Tibial and fibular shaft fractures in children. In: UpToDate, Boutis, K, Wiley, JF. Waltham, MA, 2022.