

THIS IS... ORTHO

JEOPARDY!

WITH YOUR HOST, SARAH BOLANDER

JEOPARDY!

JEOPARDY!

JEOPARDY!

JEOPARDY!

JEOPARDY!

JEOPARDY!

\$ 200

\$ 200

\$ 200

\$ 200

\$ 200

\$ 200

\$ 400

\$ 400

\$ 400

\$ 400

\$ 400

\$ 400

\$ 600

\$ 600

\$ 600

\$ 600

\$ 600

\$ 600

\$ 800

\$ 800

\$ 800

\$ 800

\$ 800

\$ 800

\$ 1000

\$ 1000

\$ 1000

\$ 1000

\$ 1000

\$ 1000



JEOPARDY!

MUSCULOSKELTAL BASICS

JEOPARDY!

CLINICAL PRESENTATION

JEOPARDY!

**SPECIALIZED
PHYSICAL EXAM
TECHNIQUES**

JEOPARDY!

IMAGING

JEOPARDY!

**DIAGNOSIS
AND
TREATMENT**

JEOPARDY!

EPONYMS

SENSORY OF THIS NERVE
IS ASSESSED ON THE
DORSUM OF THE HAND

Ortho Jeopardy

WHAT IS:
RADIAL NERVE?

\$ 200

THESE ARE THE NAMES OF THREE
INCOMPLETE FRACTURES
COMMONLY SEEN IN PEDIATRICS

Ortho Jeopardy

WHAT ARE:
GREENSTICK, TORUS,
AND BOWING

\$ 400

THIS IS THE MOST COMMON
BACTERIAL PATHOGEN IN
SEPTIC ARTHRITIS

Ortho Jeopardy

WHAT IS:

Staphylococcus aureus

\$ 600

THE BONE INVOLVED IN KIENBÖCK DISEASE

Ortho Jeopardy



WHAT IS:
LUNATE

\$ 800

MOTOR FUNCTION OF
THIS NERVE IS TESTED
BY MAKING THE “OK”
SIGN

Ortho Jeopardy

WHAT IS:
ANTERIOR INTEROSSEOUS
NERVE (AIN)

\$ 1000

THIS BONE IS PALPABLE
WITHIN THE ANATOMIC
SNUFFBOX

Ortho Jeopardy

WHAT IS:
SCAPHOID

\$ 200

THIS IS THE MOST
COMMON CAUSE OF
PEDIATRIC LIMP

Ortho Jeopardy

WHAT IS:
TRAUMA

\$ 400

THE LOCATION OF PAIN IN SEVER'S DISEASE

Ortho Jeopardy

WHAT IS:
CALCANEAL
APOPHYSIS

\$ 600

DIFFERENTIATES STABLE FROM UNSTABLE HIP IN SCFE

Ortho Jeopardy

WHAT IS:
WEIGHT BEARING

\$ 800

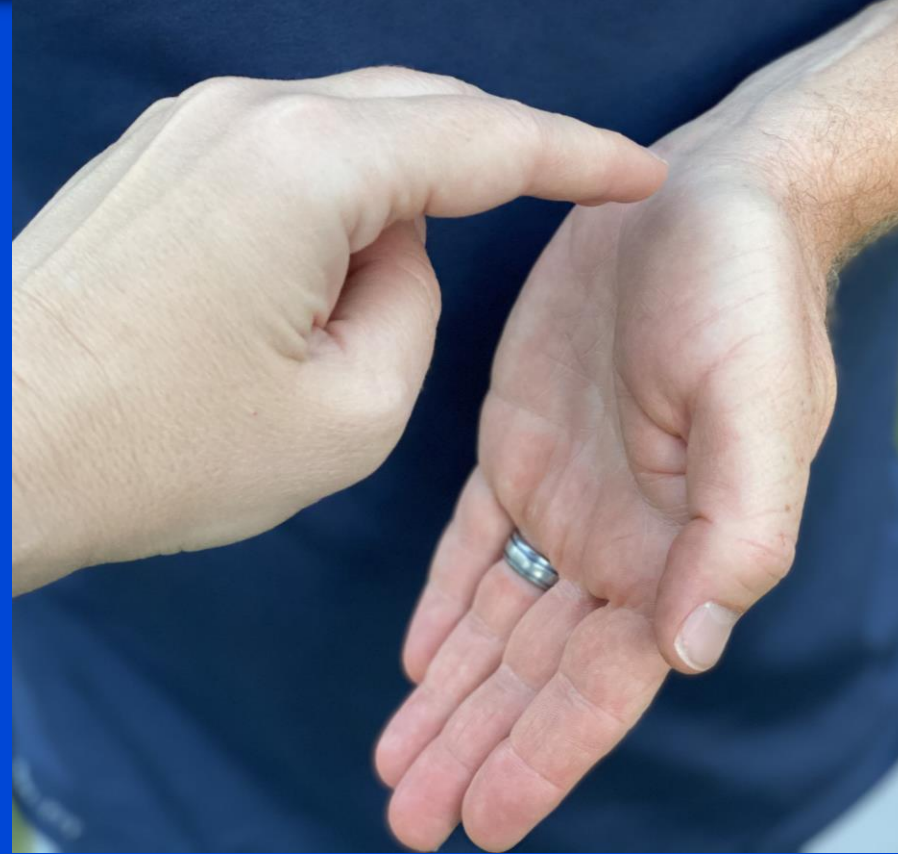THE MECHANISM OF INJURY PICTURED IS AT HIGHEST RISK FOR CAUSING WHICH PEDIATRIC INJURY



Ortho Jeopardy

WHAT IS:
TODDLER FRACTURE

\$ 1000

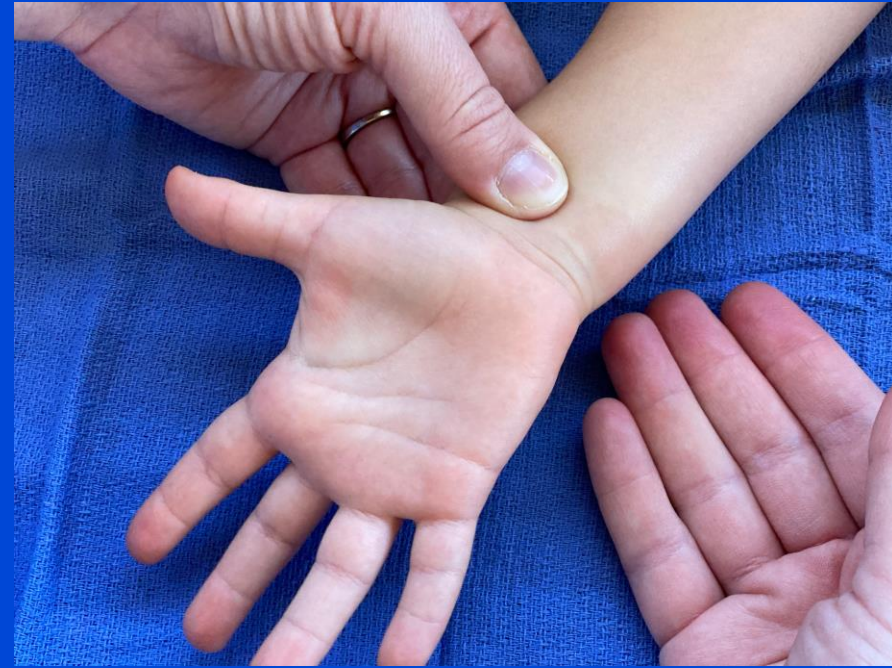
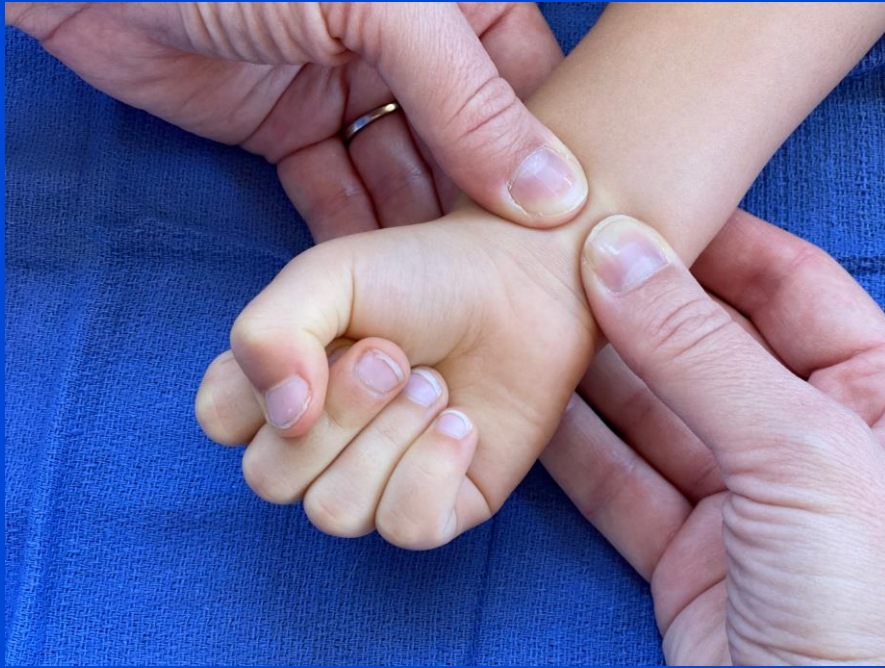
THIS TEST ASSESS FOR CARPAL TUNNEL

Ortho Jeopardy

WHAT IS:
TINEL

\$ 200



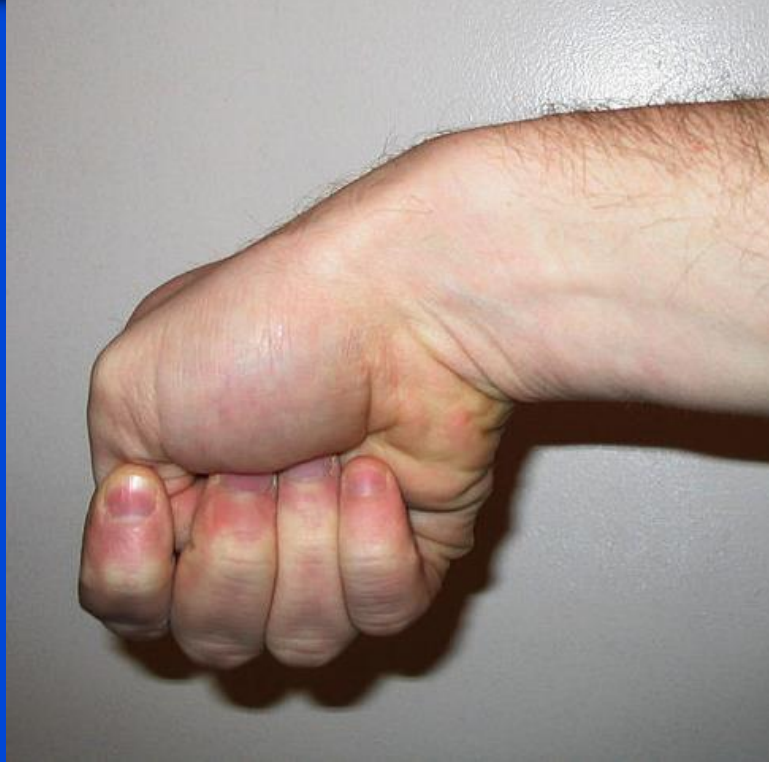THE ARTERIAL BLOOD SUPPLY OF THE
HAND IS ASSESSED BY THIS TEST

Ortho Jeopardy

WHAT IS:

ALLEN

\$ 400

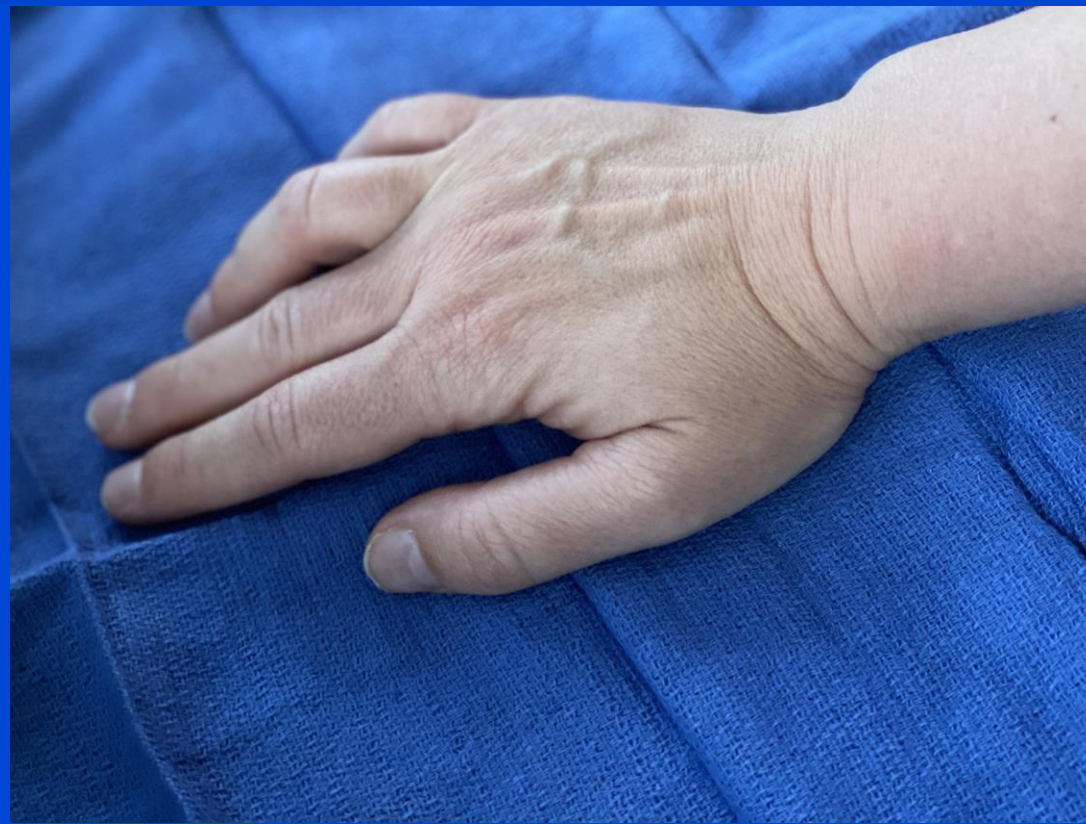

THE CONDITION ASSESSED BY THE
SPECIALIZED TEST PICTURED

Ortho Jeopardy

WHAT IS:
DE QUERVAIN'S
TENOSYNOVITIS

\$ 600



THE PICTURED TEST ASSESSES FOR
THIS CONDITION

Ortho Jeopardy



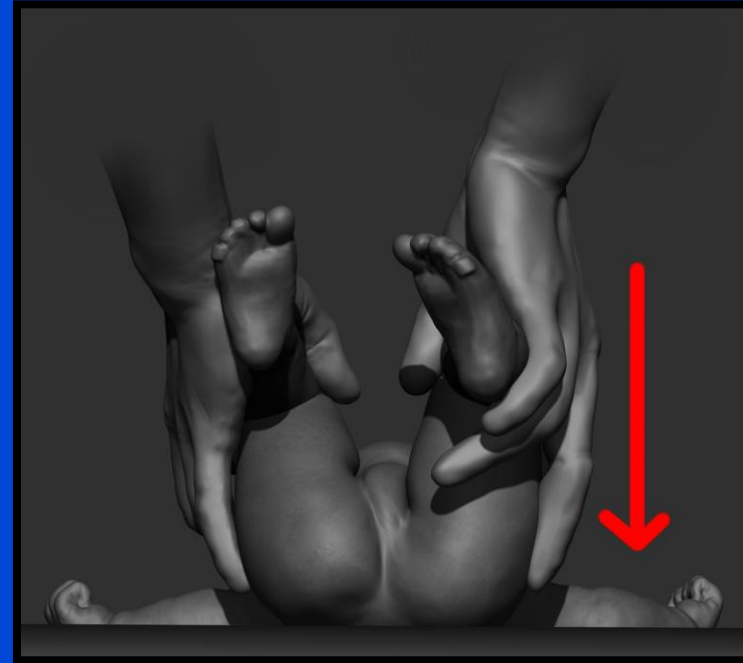
WHAT IS:
DUPUYTREN'S
CONTRACTURE

\$ 800

**PROVOCATIVE MANEUVER FOR DDH
PERFORMED WITH HIP FLEXION,
ADDUCTION, AND POSTERIOR PRESSURE**

Ortho Jeopardy

WHAT IS:
BARLOW



\$ 1000

THIS IS THE INITIAL IMAGING
OF CHOICE FOR MAJORITY OF
MUSCULOSKELETAL INJURIES

Ortho Jeopardy

WHAT IS:
PLAIN RADIOGRAPHS

\$ 200

TERM TO DESCRIBE
MORE THAN 2
FRACTURE FRAGMENTS

Ortho Jeopardy

WHAT IS:

COMMUNUTED

\$ 400

DISPLACEMENT IS DESCRIBED BY THE
POSITION OF THIS FRACTURE FRAGMENT

Ortho Jeopardy

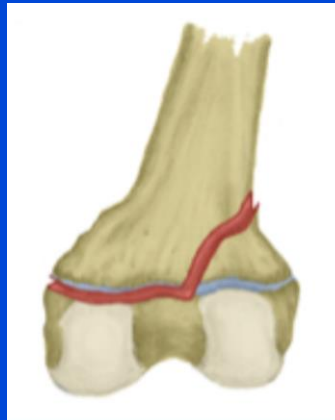WHAT IS:
DISTAL

\$ 600

SALTER-HARRIS
CLASSIFICATION FOR
FRACTURE INVOLVING
METAPHYSIS AND PHYSIS

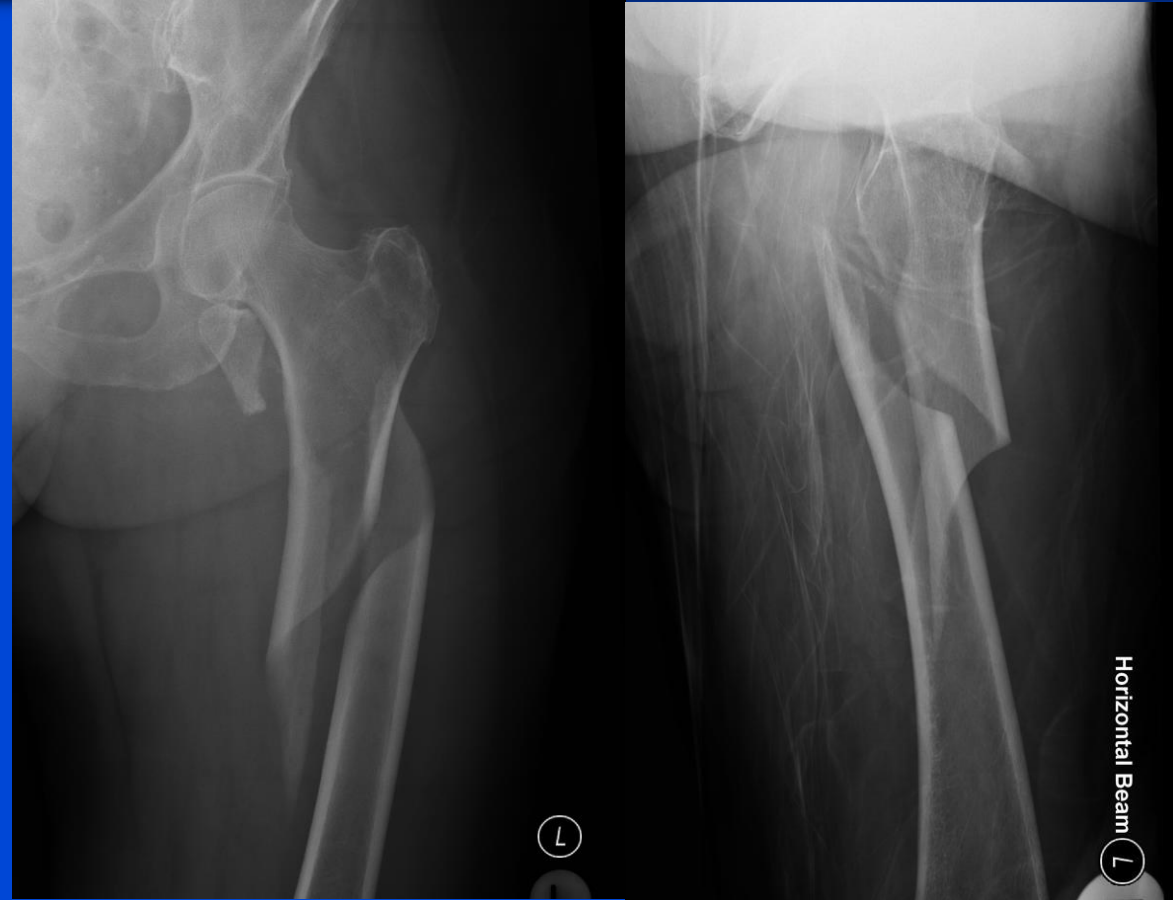Ortho Jeopardy

WHAT IS:



TYPE II

\$ 800



THESE ARE THE FRACTURE PATTERNS IMAGED

Ortho Jeopardy

Case courtesy of Dr Andrew Dixon, Radiopaedia.org, rID: 25704

WHAT IS:
SPIRAL AND AVULSION

\$ 1000

**DEBRIDEMENT AND IRRIGATION IS
REQUIRED FOR THIS FRACTURE
COMPLICATION**

Ortho Jeopardy

WHAT IS:
OPEN FRACTURE

\$ 200

JUVENILE IDOPATHIC
OSTEONECROSIS OF THE FEMORAL
HEAD DEFINES THIS CONDITION

Ortho Jeopardy



WHAT IS:
LEGG-CALVE-PERTHES

\$ 400

MAINSTAY TREATMENT FOR
DEVELOPMENTAL DYSPLASIA
OF THE HIP IN A NEWBORN
RECOMMENDS THIS DEVICE

Ortho Jeopardy

WHAT IS:
PAVLIK HARNESS

\$ 600

THESE ARE THE FOUR
COMPONENTS OF KOCHER
CRITERIA

Ortho Jeopardy

WHAT IS:

WBC >12,000

ESR >40

FEVER >101.3

NONWEIGHTBEARING

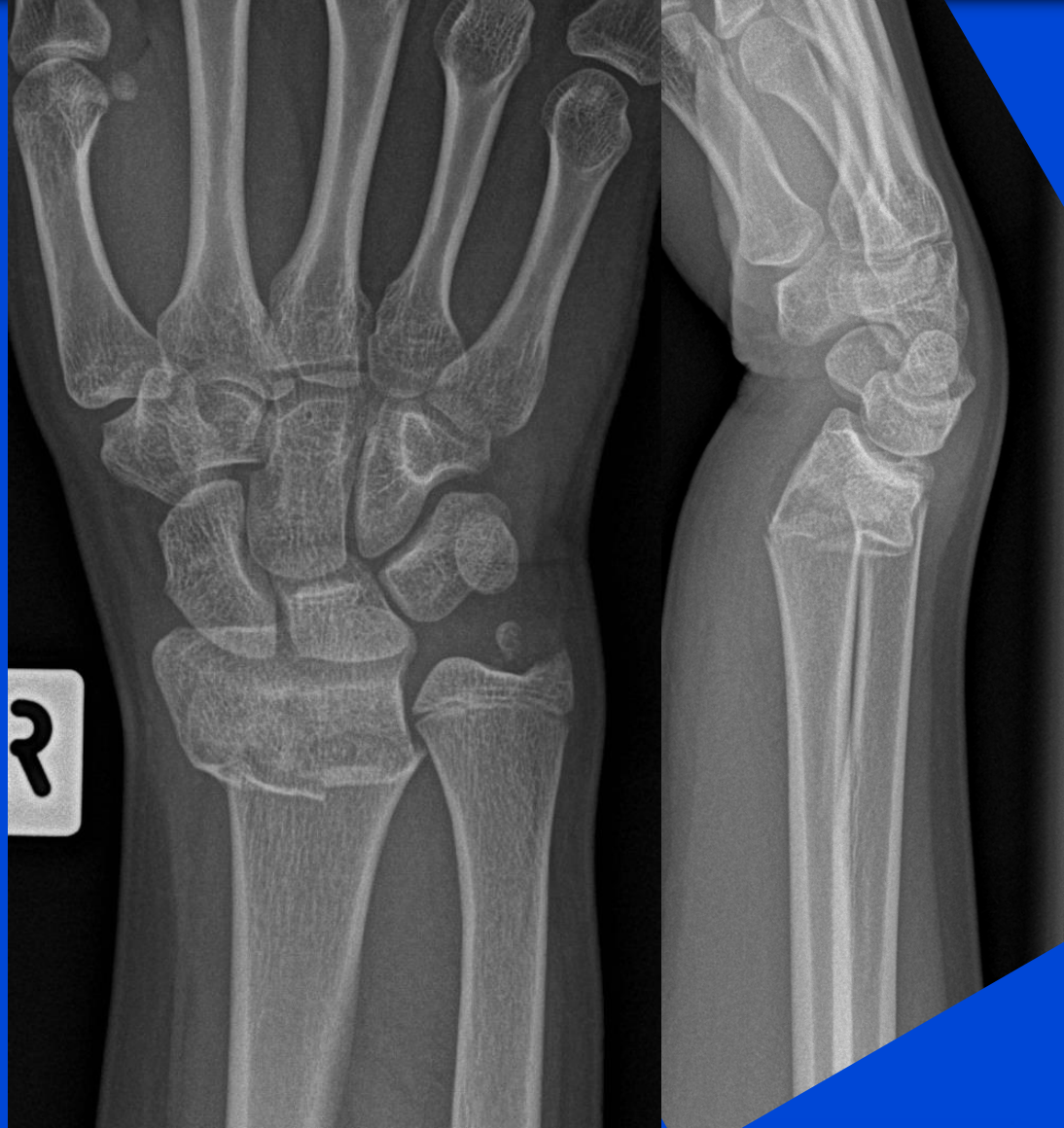\$ 800

THIS IS SURGICALLY
RELEASED IN MANAGEMENT
OF TRIGGER FINGER

Ortho Jeopardy

WHAT IS:
A1 PULLEY

\$ 1000

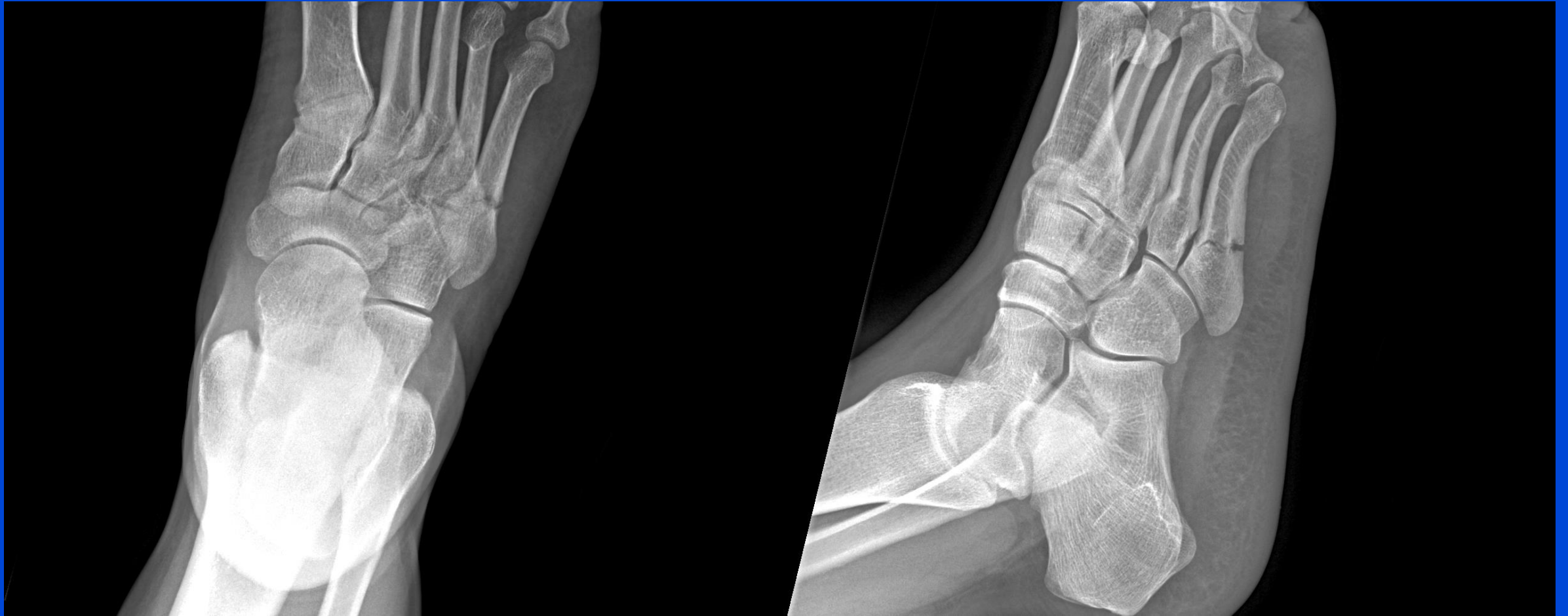

Ortho Jeopardy

Case courtesy of Townsville radiology training, Radiopaedia.org, rID: 17977

WHAT IS:
COLLES FRACTURE

\$ 200

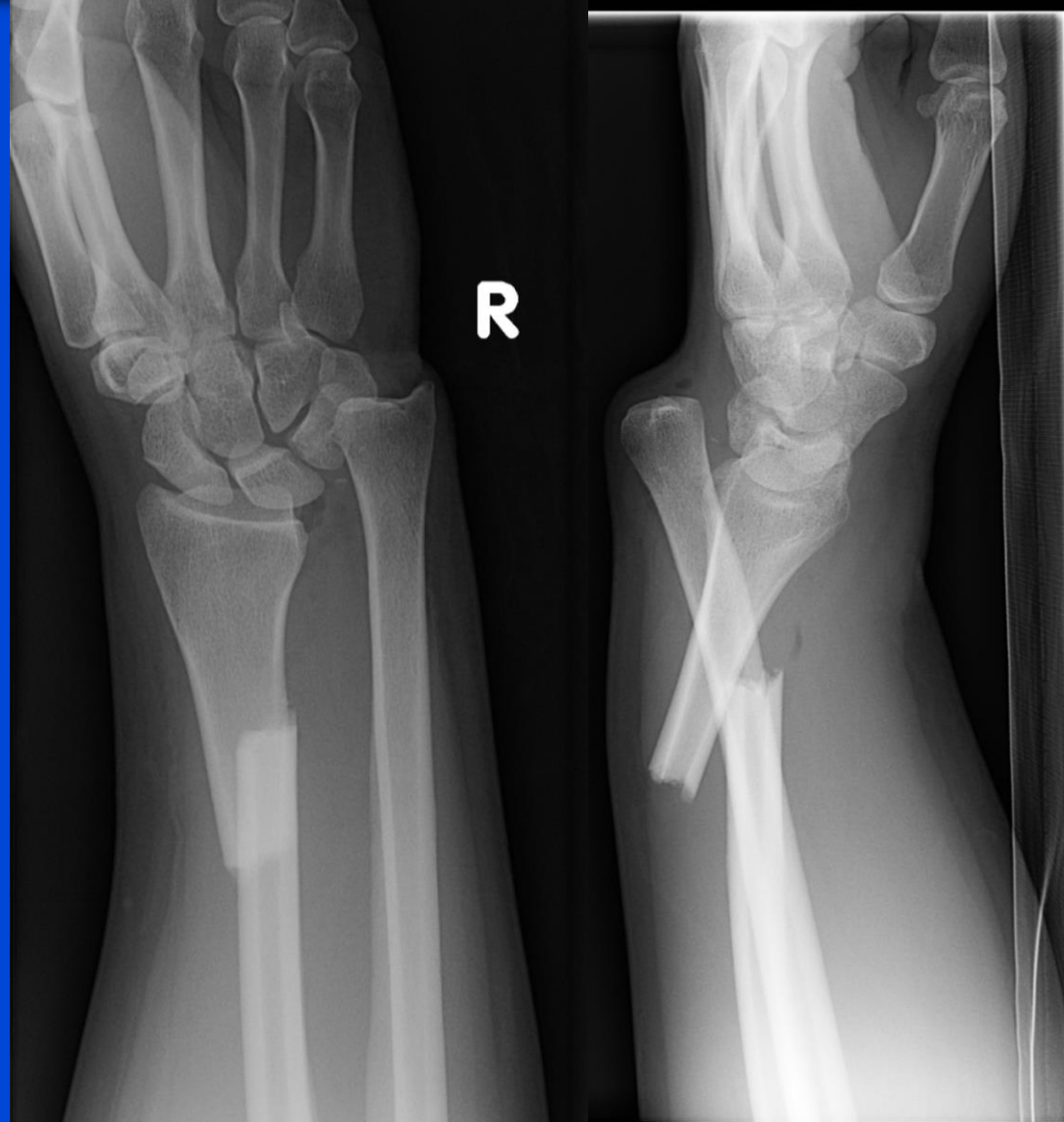

Ortho Jeopardy

Case courtesy of Dr Matt Skalski, Radiopaedia.org, rID: 35716

WHAT IS:
JONES FRACTURE

\$ 400



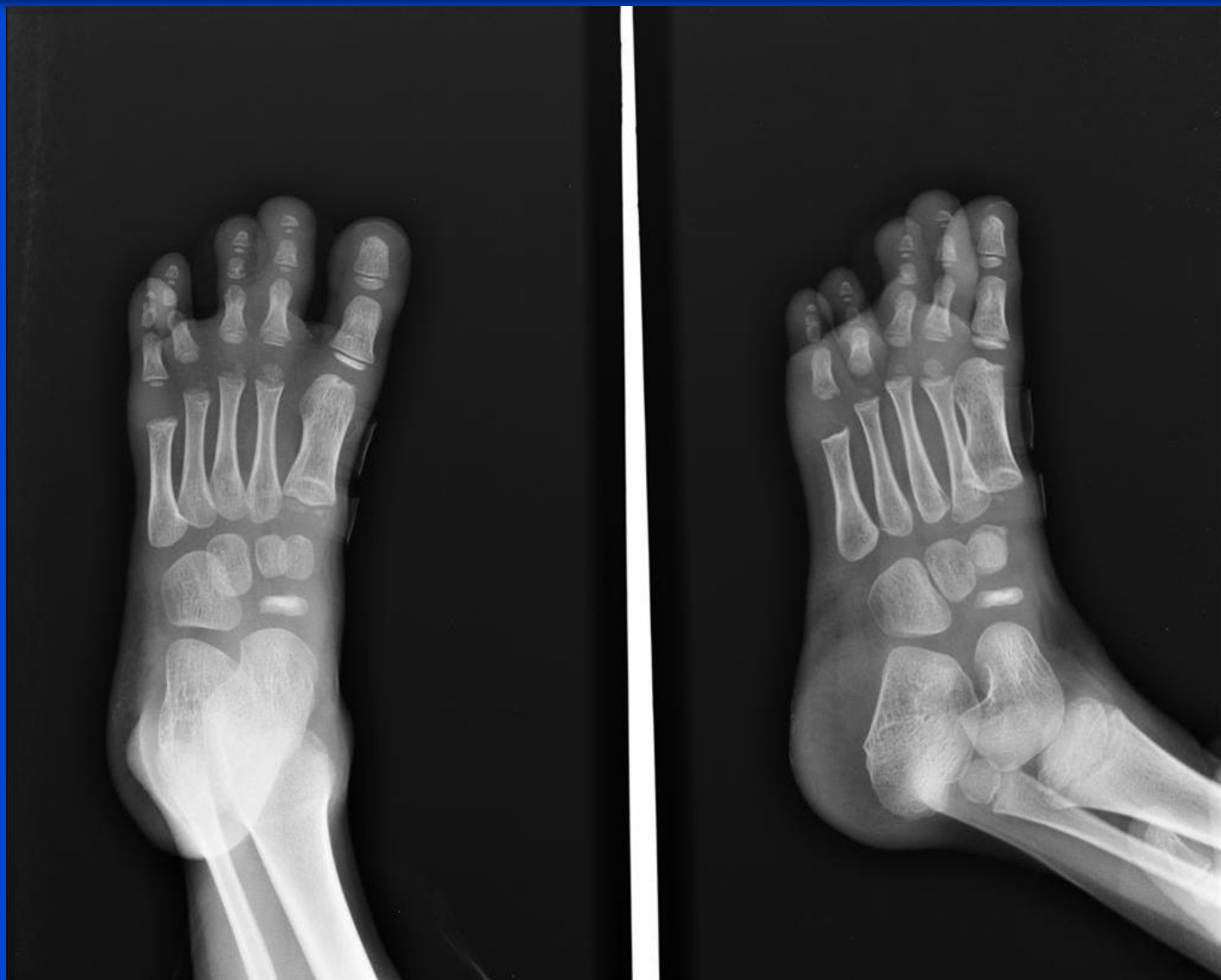Ortho Jeopardy

Case courtesy of Dr Alexandra Stanislavsky, Radiopaedia.org, rID: 10961



WHAT IS:
GALEAZZI
FRACTURE-DISLOCATION

\$ 600

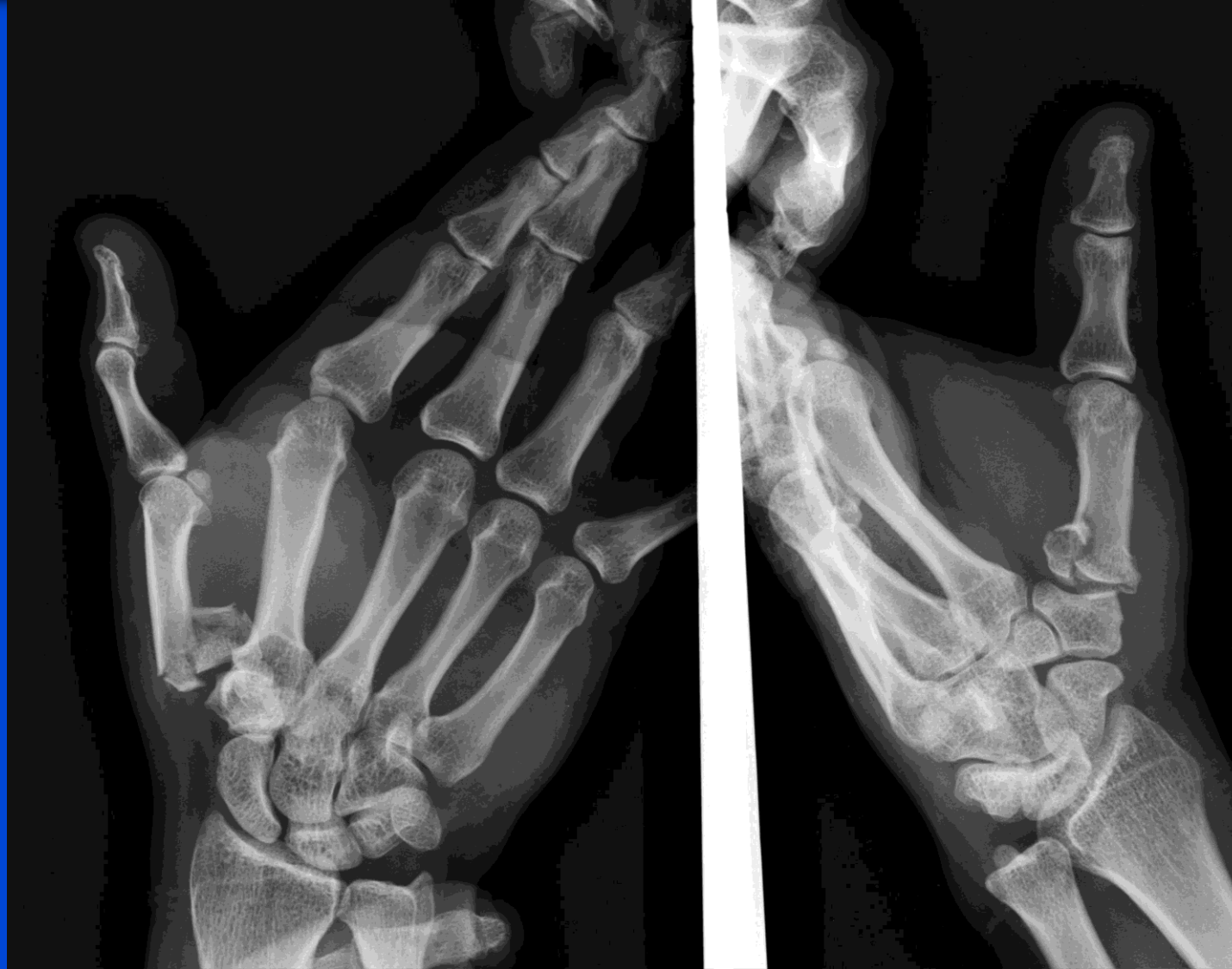

Ortho Jeopardy

Case courtesy of Dr Maulik S Patel, Radiopaedia.org, rID: 18657

WHAT IS:
KÖHLER DISEASE

\$ 800



Ortho Jeopardy

Case courtesy of Dr Maulik S Patel, Radiopaedia.org, rID: 48712

WHAT IS:
ROLANDO FRACTURE

\$ 1000

