

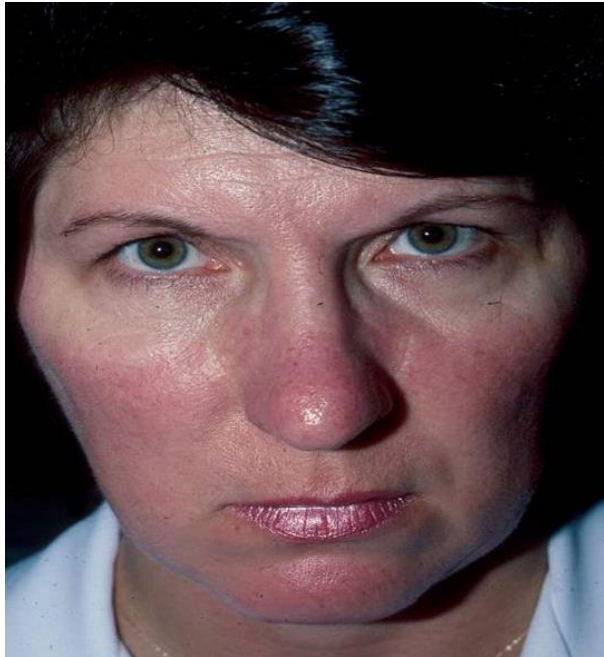
# The Usual Suspects:

Rosacea, Acne, Lichen Planus, Psoriasis, Contact Dermatitis

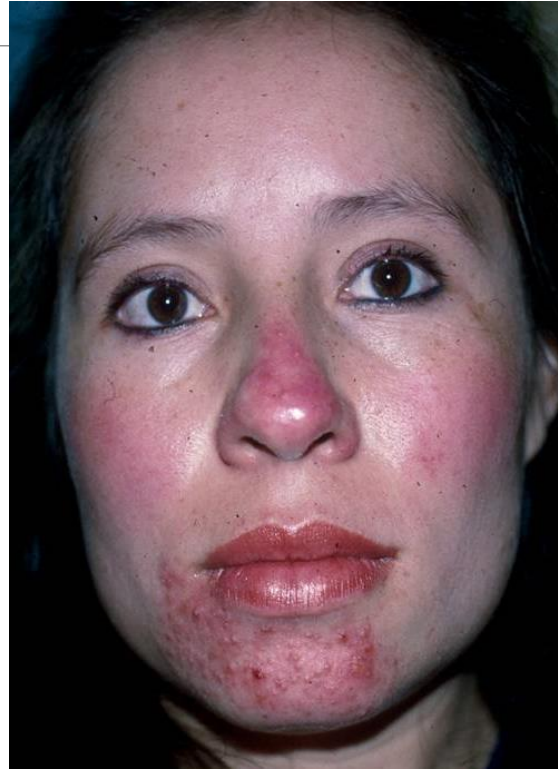---

CYNTHIA GRIFFITH MPAS, PA-C

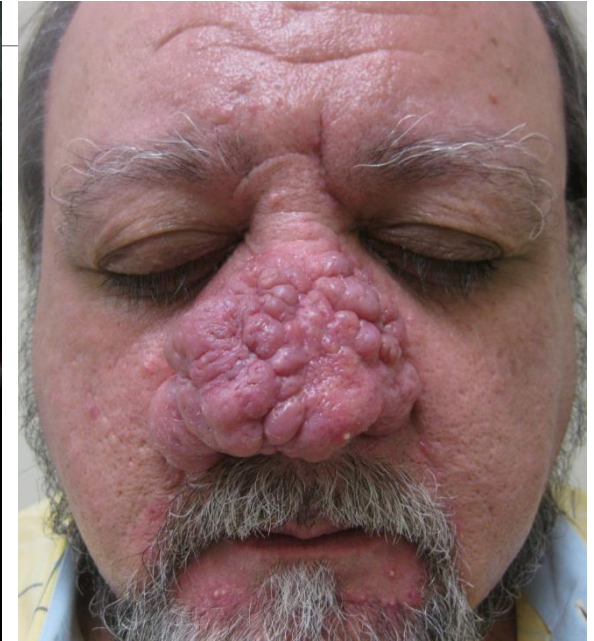
# Rosacea



Erythematelangectatic



Papulopustular



Phymatous

# Rosacea

---

- Rosacea is a chronic inflammatory condition of the face, which may present with easy *flushing*, erythema, *telangiectasias*, papules and pustules, and/or *phymatous* changes
- Can have Ocular involvement: Blepharitis, FB sensation, burning, stinging, dryness, blurred vision, styes, corneal ulceration (refer to Ophthalmology)
- No comedones, unrelated to hormones. Triggers: sun, heat, emotion chemical irritation, alcohol, strong drinks, spices

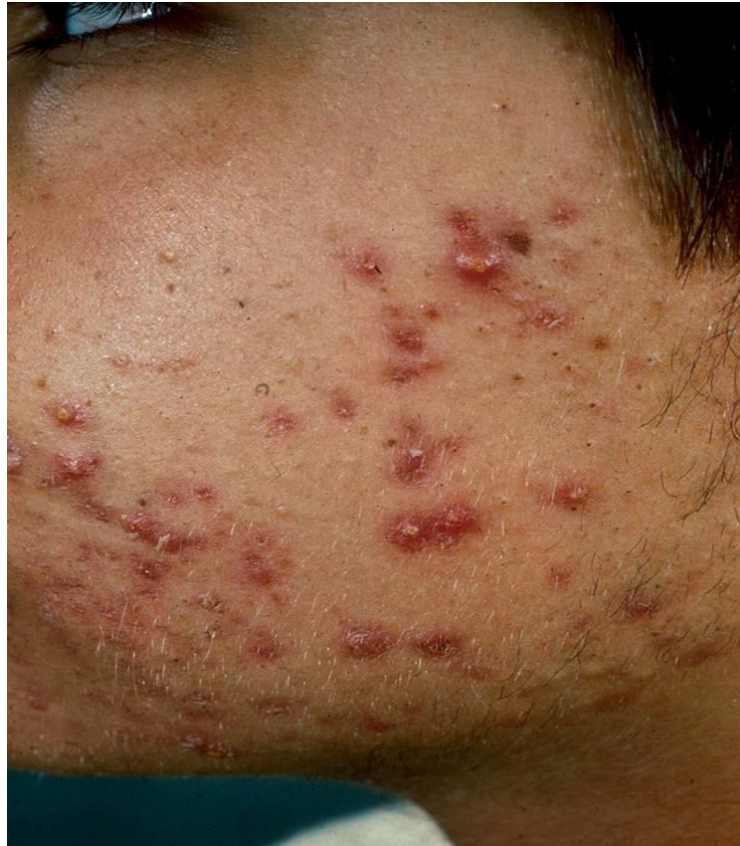# Rosacea

---

- Topical treatments: Metronidazole topical gel or cream, Sodium Sulfacetamide with %5 sulfur, Azelaic acid
- Oral treatments: Tetracyclines, macrolides
- Lasers: Pulse dye laser (Vbeam laser), Intense pulse light laser
- All patients with rosacea should use sunscreen
- Steroids can worsen or induce rosacea

# Acne Vulgaris

---



# Acne Vulgaris

---

Primary lesion: Comedone

open and closed comedones, papules, pustules, nodules, and cysts

- Include the following when describing
  - morphology
    - Comedonal vs Inflammatory (either papular/pustular or nodulocystic or mixed)
  - severity (Mild, Moderate, Severe)
  - presence of scarring
- Pathogenesis of acne vulgaris is related to the presence of androgens, excess sebum production, the activity of *P. acnes*, and follicular hyperkeratinization

# Acne Vulgaris Treatment

---

- Topical antimicrobial
  - Clindamycin, Erythromycin
- Systemic and topical retinoids – Vitamin A derivative, Tretinoin, Adapalene, Tazarotene (topical), Isotretinoin (Accutane, oral)
- Systemic antimicrobials – Tetracycline class: Minocycline, Doxycycline, Can also use Erythromycin
- Systemic hormonal therapies- Spironolactone, OCPs
- Other topical adjuncts- Benzoyl Peroxide, Azelaic Acid

# Acne

---

Acne Excoriée des Jeunes Filles

Neonatal Cephalic Pustulosis- 2 wks-3months

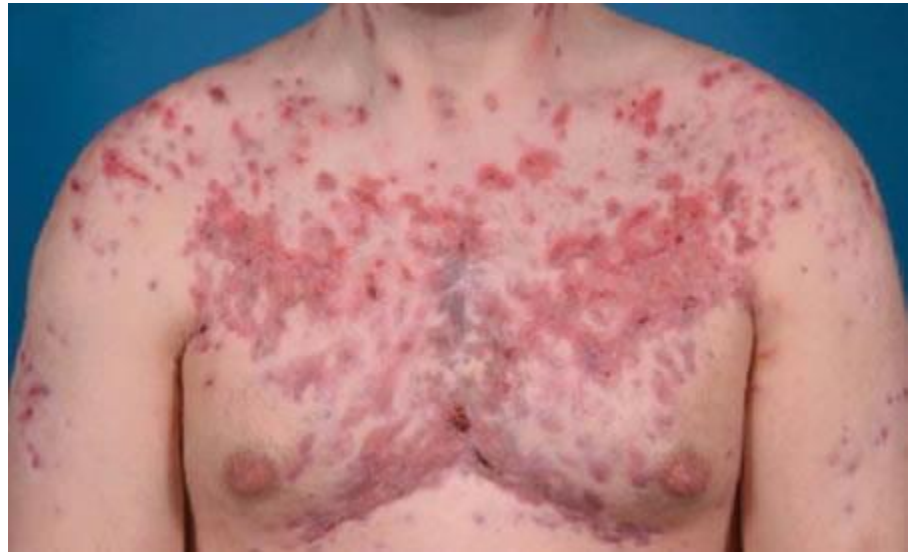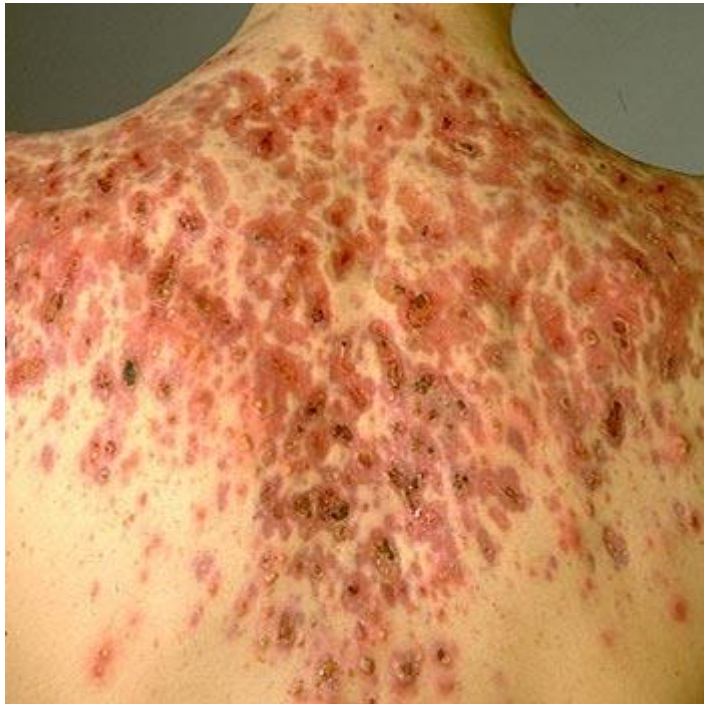Infantile acne- presents 3-6 months resolved 1-2 years

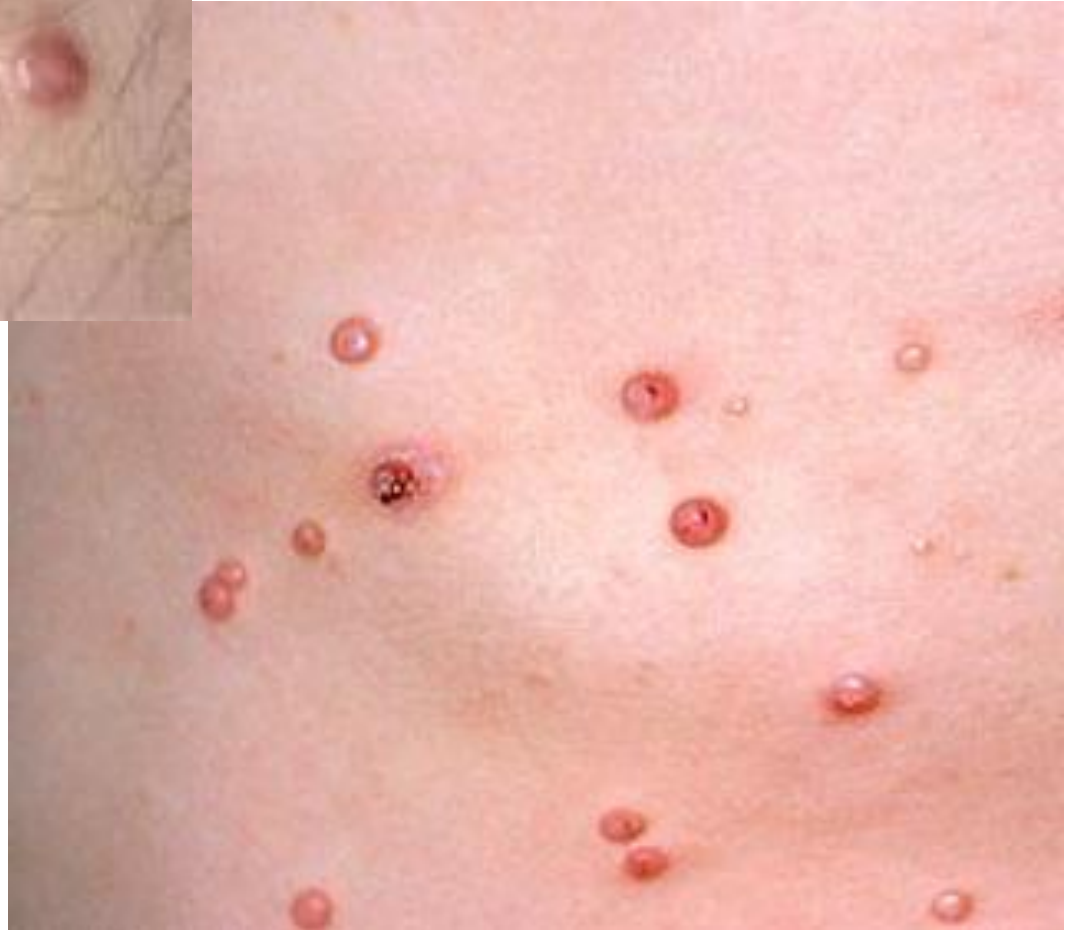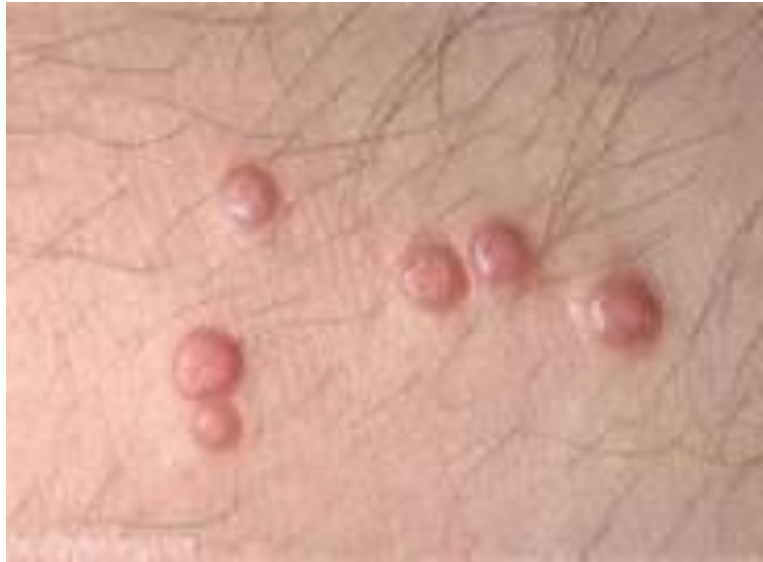Drug Induced- within 2 weeks of oral or topical steroid use, INH, phenytoin, cyclosporine, lithium, Keflex, OCPs, Androgens

Acne conglobata- Men, late puberty-early adulthood, severe acne: papules, nodules, draining sinus tracts on chest, shoulders, back, nape, buttock. No system symptoms

Acne Fulminans- Acute Febrile Ulcerative Acne, Conglobata with systemic symptoms (fever, leukocytosis, myalgias, arthralgias, osteolytic lesions)





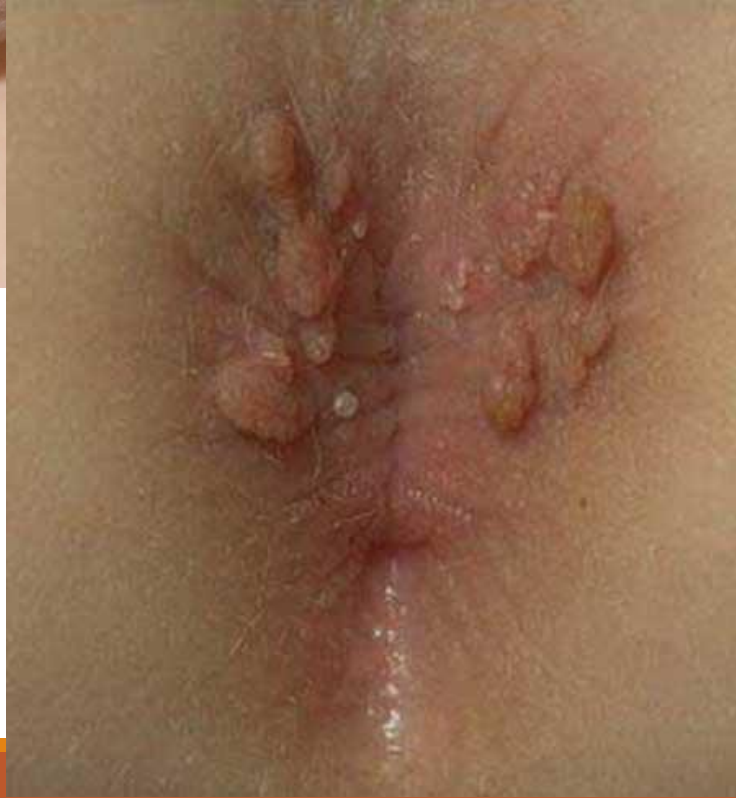
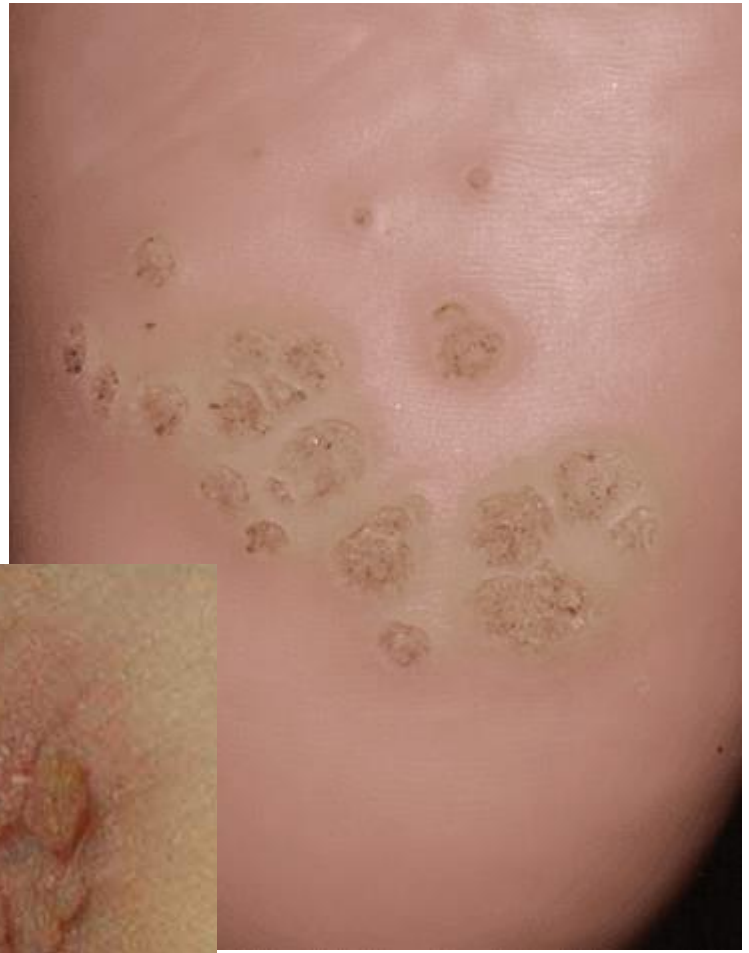
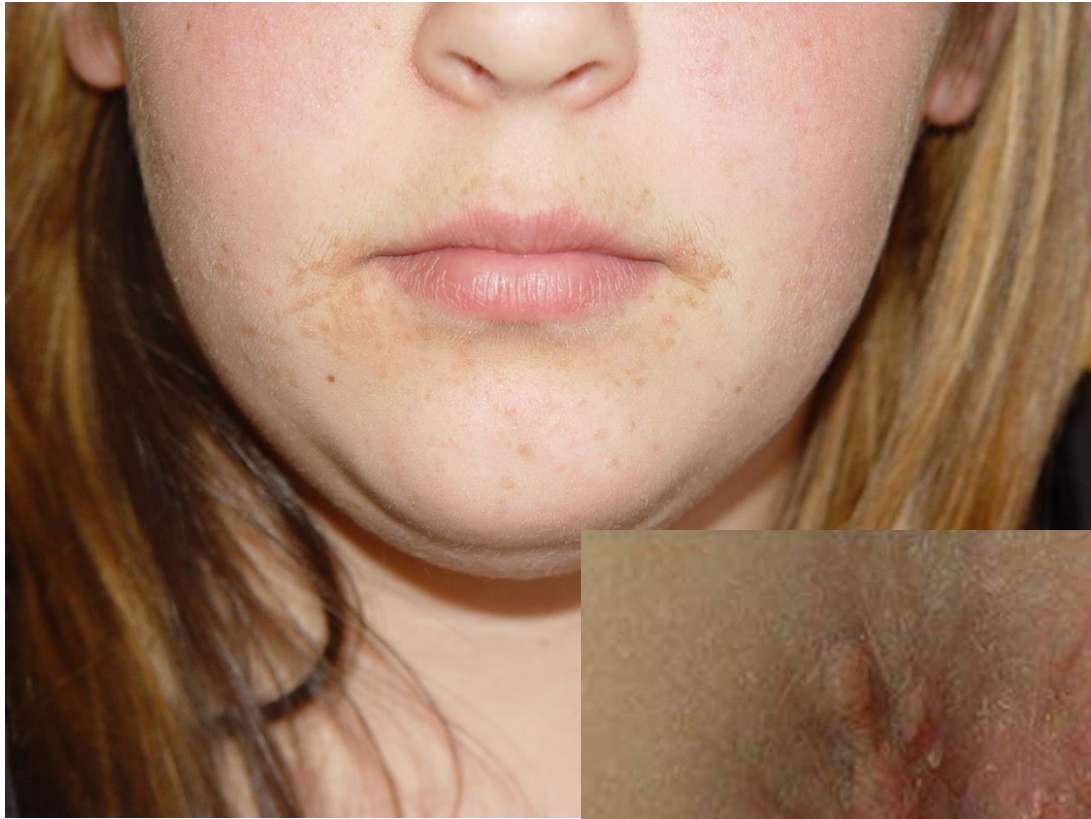# Molluscum Contagiosum

---

single or, more often, multiple, rounded, dome-shaped, *umbilicated*, pink papules that are 2-5 mm

- Viral infection due to a pox virus, transmitted by skin to skin contact
- Three main groups at risk (children, sexually active adults and immunosuppressed patients)
- Various treatment options available
  - Cryotherapy, Cantharidin, Curettage, Topical retinoids, Imiquimod
- In children spontaneous remission frequently occurs and no treatment is a reasonable option



# Verruca (Warts)

---

Types: Common (*Vulgaris*), Plantar (*Plantaris*), Flat (*Plana*), Genital

	HPV virus
Common	HPV-1, 2, 4
Plantar	HPV-1, 2, 4
Flat	HPV-3, 10
Genital	HPV-16 and 18

- Treatments: Watchful waiting, Cryotherapy, Salicylic Acid, 5-fluorouracil cream, Imiquimod, Electrocautery and curettage, diphencyprone (DCP) Immunotherapy

Also viral etiology similar to Molluscum (worse with Immunosuppression)

# Verruca (Warts)

---

Common Warts *Verruca Vulgaris*: hyperkeratotic, exophytic, dome shaped, *verrucous appearing* papule on the fingers, dorsal hands, elbows, knees, with *punctate black dots*

Flat warts *Verruca Plana*: skin colored or pink flat topped papules common on the dorsal hands, face and arms



# Lichen Planus

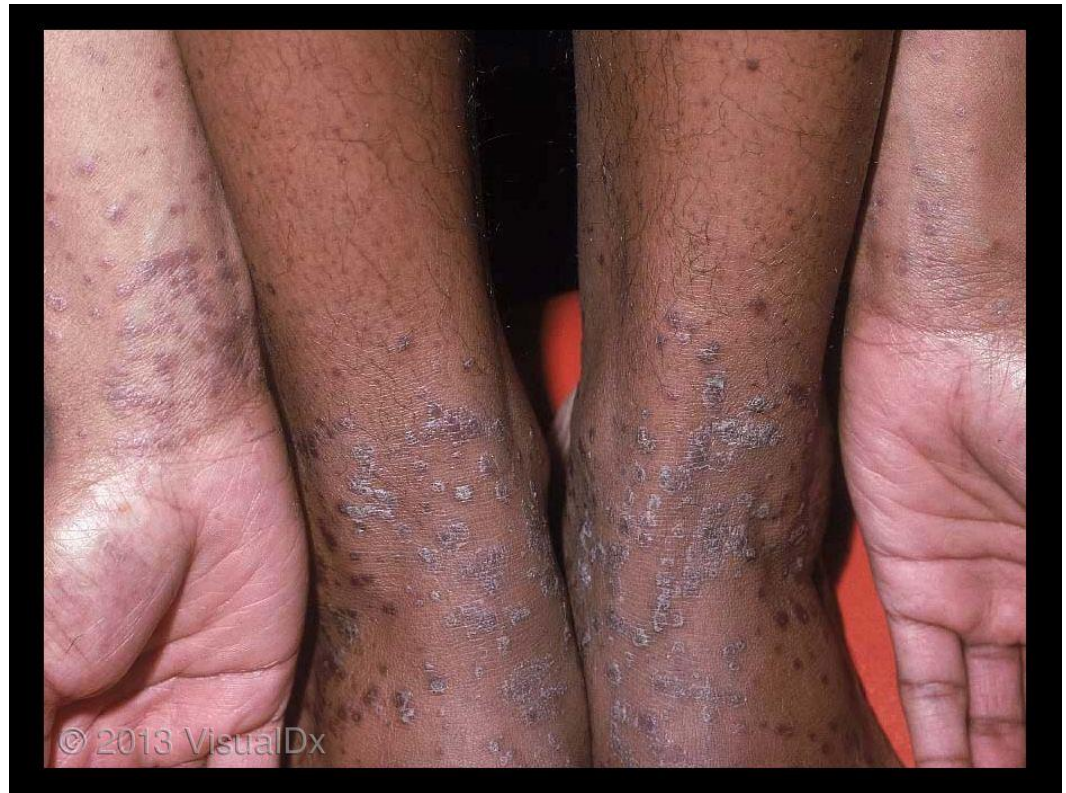---

Acute and sometimes chronic inflammatory dermatosis of the skin and/or nails and mucous membranes

5 P's: Planar (flat topped), Pruritic, Polygonal, Purple (violaceous) Papules

Associated with Hepatitis C infection

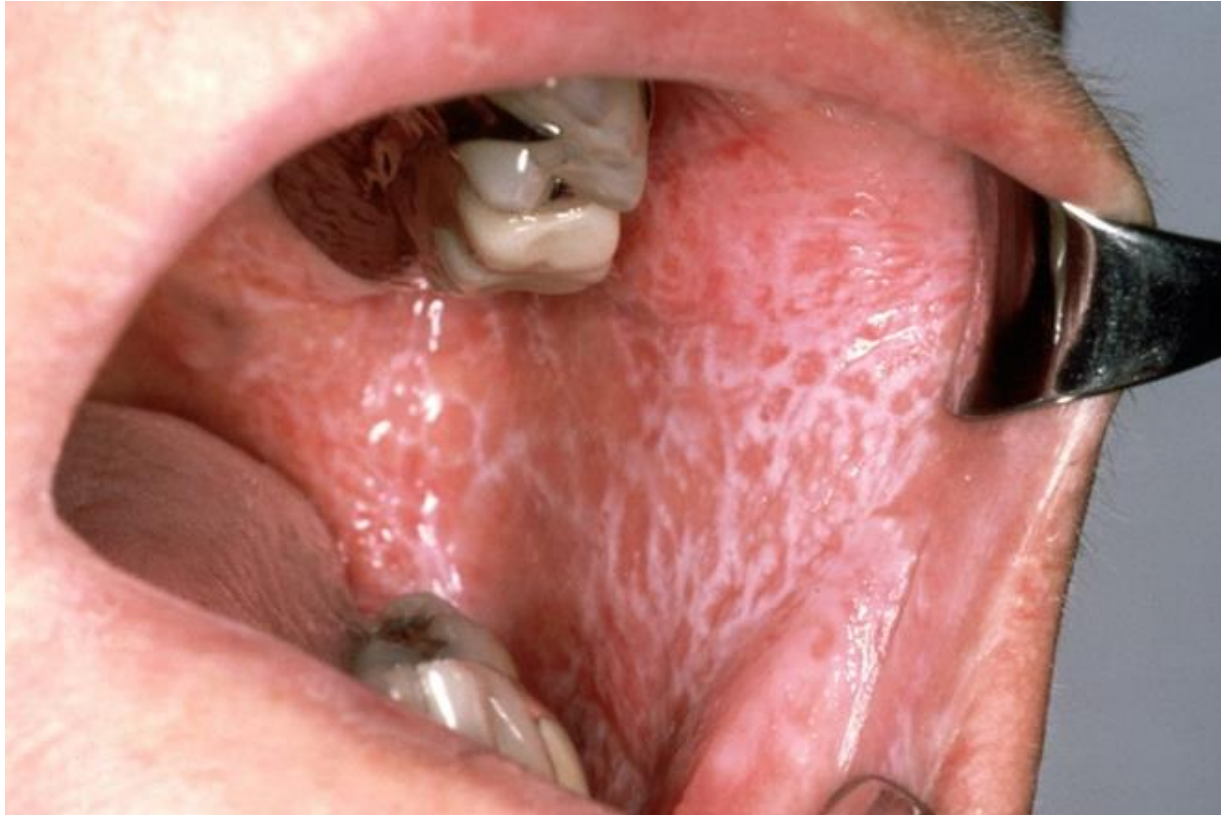Typically on the flexor wrists, low back, penis/vagina, nails, lower legs



# Lichen Planus – Wickham Striae

---

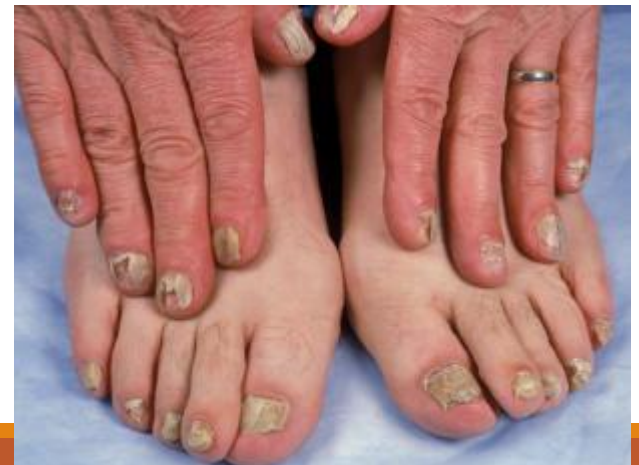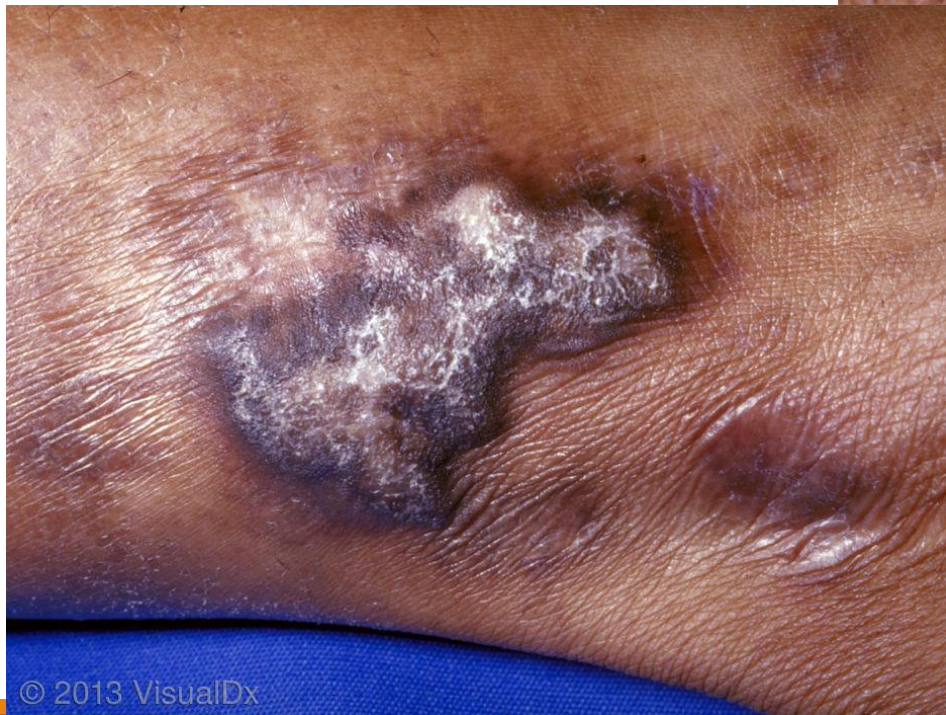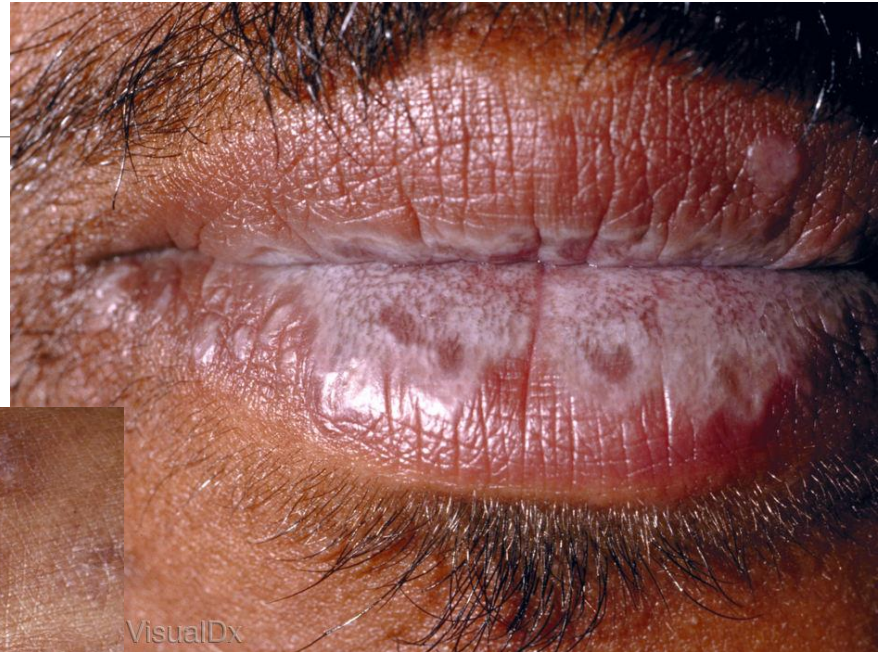Wickham striae - Lacy white reticulated pattern, visible on mucosal surfaces on within lesion lesions





# Lichen Planus

---



© 2013 VisualDx

# Lichen Planus Treatment:

---

Topical steroids

Oral Steroids

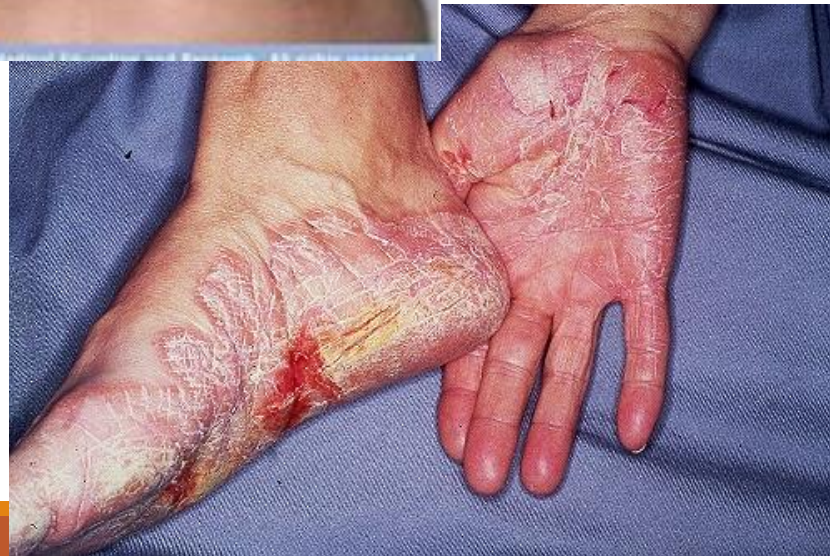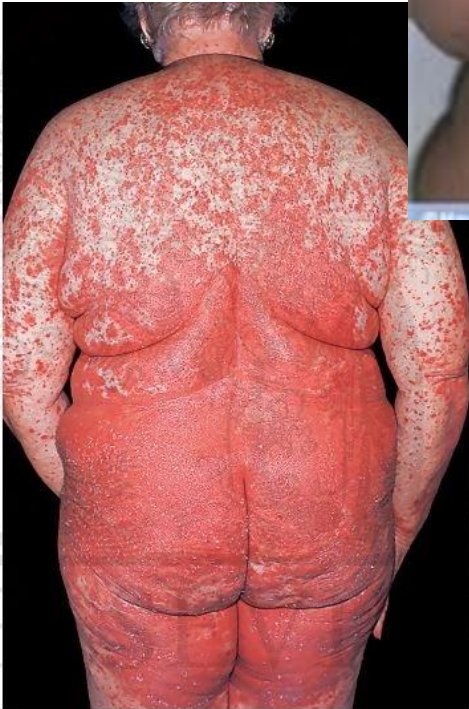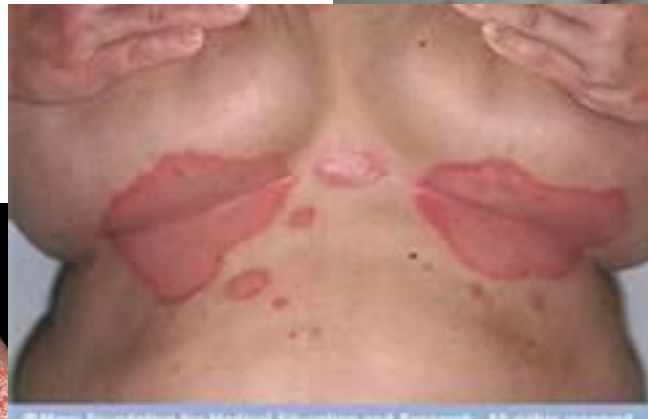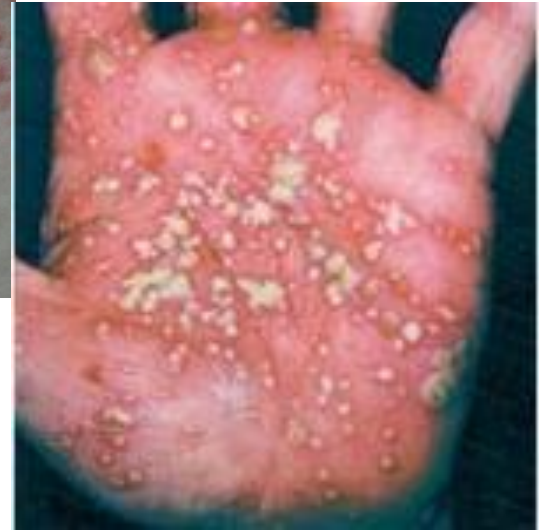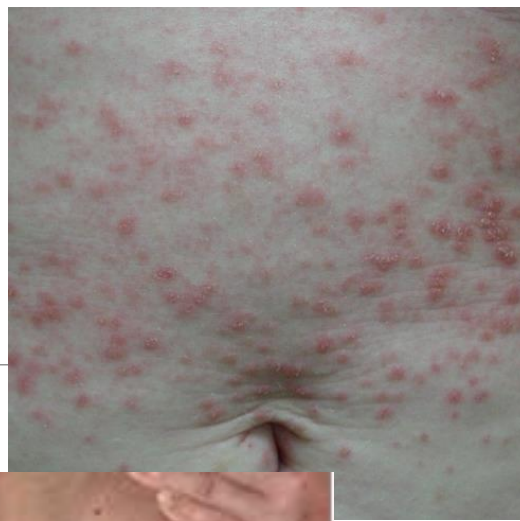Cyclosporine

System Retinoids

PUVA



# Psoriasis



# Psoriasis

---

Clinical description: Sharply demarcated thick papules and plaques with *silvery scale*

Pathogenesis: large number of activated T cells, which appear to be capable of inducing keratinocyte proliferation this hyperproliferative state results in thick skin and excess scale

Auspitz sign –pinpoint fine bleeding upon removal of scale

Woronoff's ring – concentric blanching of the erythematous skin at or near periphery of healing psoriasis plaque

# Things that can Trigger/Aggravate Psoriasis

---

Skin injury (Keobner phenomenon)

Streptococcal infections

HIV

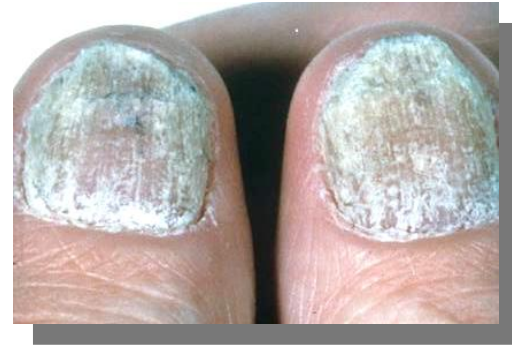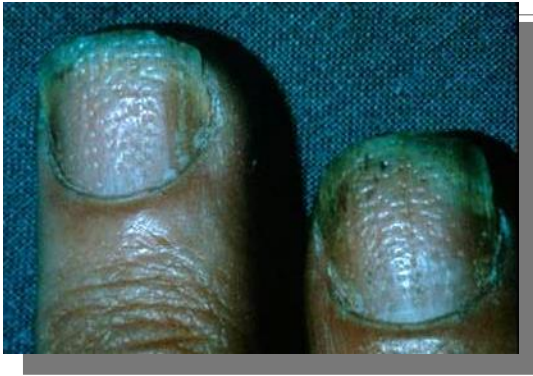Hypocalcemia can trigger generalized pustular psoriasis

Stress

Lithium, B-blockers, antimalarials, interferon, ACE-Inhibitors, gemfibrozil, NSAIDS, imiquimod, Rituximab , rapid taper of corticosteroids

ETOH, Smoking, obesity

# Nail changes in Psoriasis



- Pits (most common finding) punctuate depressions of the nail plate surface
- Oil spots (most specific finding) yellow brown discoloration
- Trachyonychia: rough nails as if scraped with sandpaper longitudinally
- Onycholysis: separation of the nail plate from the nail bed
- Subungual hyperkeratosis: abnormal keratinization of the distal nail bed

Nail Changes classically associated with Psoriatic Arthritis

# Psoriatic Arthritis

---

A seronegative spondyloarthropathies (Rheumatoid Factor negative)

Characterized by Enthesitis –inflammation involving periarticular structures i.e. tendons ligaments at their insertion points.

Most common pattern of arthritis is asymmetric oligoarthritis (mainly hands and feet)

Will cause inflammation of the DIP joints (different from RA, similar to OA or Reactive Arthritis)

Inflammation of the DIP and PIP joints = Dactylitis (sausage digit)

Pencil in cup changes on radiograph (late disease)

Arthritis mutilans – also seen in RA, shortening of the phalynx

# Psoriasis

---

Total Body Surface Area (TBSA) - measured by estimating the area of the patient's body that is affected by psoriasis using the unit 1%=1 of the patient's palm

Treatment:

Less than %5 BSA

Topical high potency steroids +/- calcipotriene (a vitamin D analog)



# Psoriasis

---

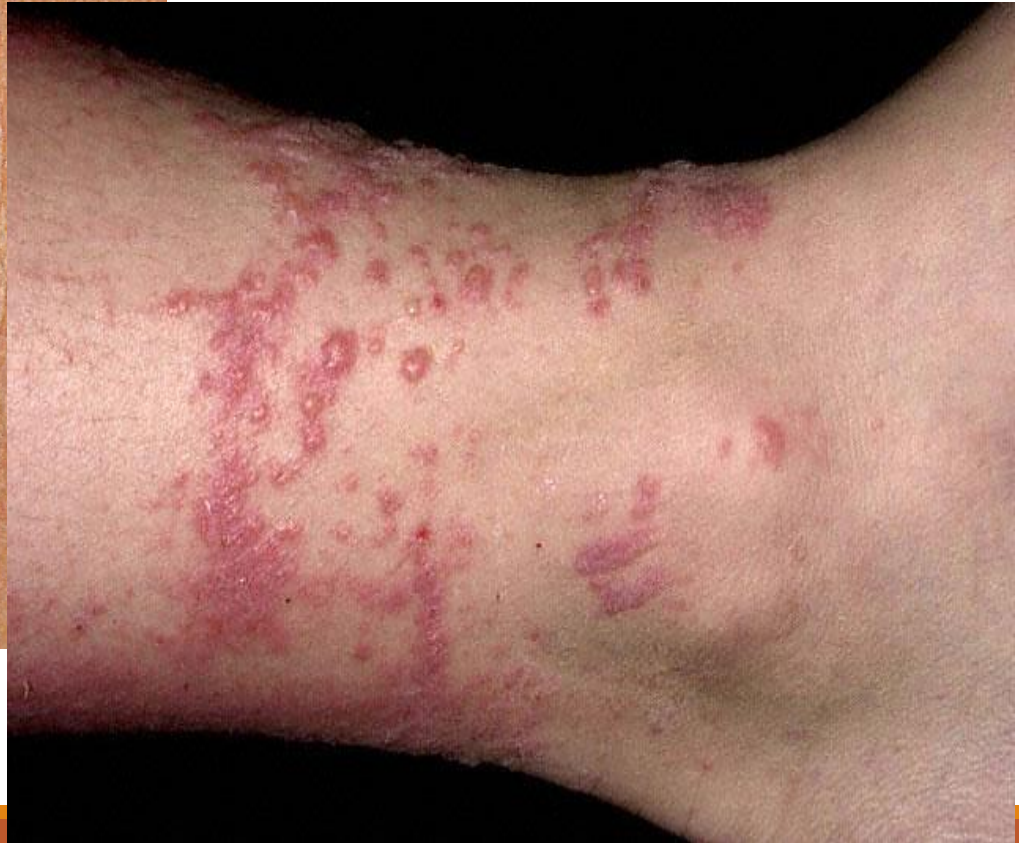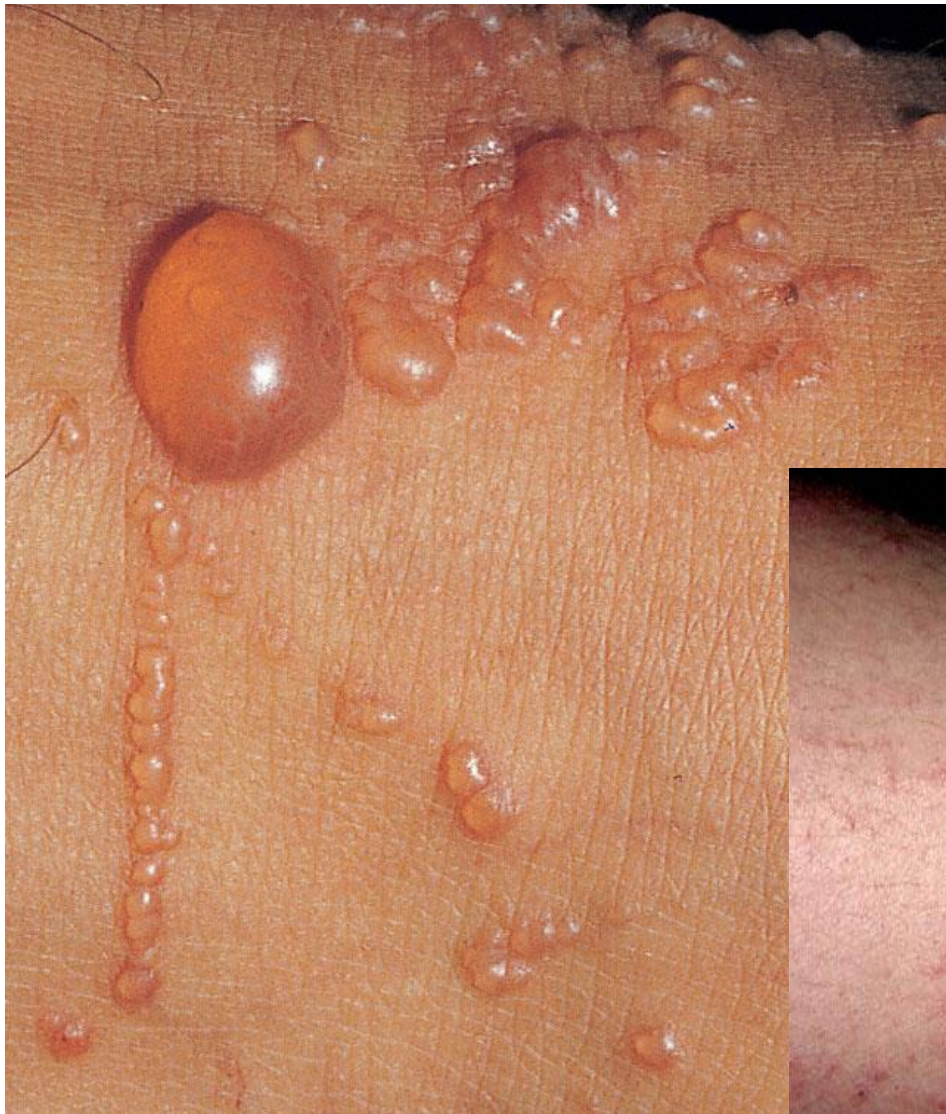Total Body Surface Area (TBSA) - measured by estimating the area of the patient's body that is affected by psoriasis using the unit 1%=1 of the patient's palm

Treatment: Greater than 5% BSA

Systemic therapy - Phototherapy NBUVB, bbUVB, PUVA,

Oral medications: Methotrexate (Folate analog, immunosuppressant) , Acitretin (Oral Retinoic, Vitamin A derivative), Cyclosporine (immunosuppressant), Apremilast (inhibits phosphodiesterase 4)

Biologic Agents TNF- $\alpha$  inhibitors: infliximab, etanercept, adalimumab, IL 12/23 blocker: ustekinumab



# Contact Dermatitis

---

Types of dermatitis or eczematous conditions:

seborrheic, atopic, dyshydrotic, nummular, contact...

Two types of Contact Dermatitis : Irritant and Allergic

Irritant	Allergic
<p>Type of dermatitis may be induced in any person if a sufficiently high concentration is used.</p> <p>No previous exposure is necessary</p> <p>Effect is evident within minutes, or a few hours at most.</p>	<p>Delayed hypersensitivity reaction</p> <p>Requires initial exposure</p> <p>The sensitization process requires 10-14 days</p> <ul style="list-style-type: none"> <li>• Upon re-exposure, dermatitis appears within 12-48 hrs</li> </ul>
<p>Pain, burning</p>	<p>Itching</p>
<p>Classically more common than Allergic Contact dermatitis</p>	
<p>ICD remains at the site of contact and resolves in a few days after exposure</p>	<p>Can last 1-3 weeks with ACD</p>
<p>Examples soaps, detergents, bleaches, capsaicin (pepper spray), acid,</p>	<p>Common: nickel, fragrance, gold, rhus (poison ivy)</p>

# Contact Dermatitis

---

Rhus (poison ivy) allergic contact dermatitis – treat with oral prednisone for 2-3 weeks duration

Topical Steroids

Avoidance of the allergen – Patch testing

Patch testing

Day 1 application - leave patches on 48 hours

Day 3 remove patches initial reading,

Day 5 final reading

Avoidance of allergen + resolution of rash = clinically relevant allergen

# Allergen of the Year

---

2019 - Dimethyl fumarate: Inhibits mold, used to treat psoriasis, “Poison chairs”

2010 – Neomycin: (antibiotic)

2009 – Mixed dialkyl thioureas: (Neoprene rubber is a common source.)

2008 – Nickel

2007 – Fragrance

2006 – p-Phenylenediamine

2005 – Corticosteroids

2004 – Cocamidopropyl betaine: yellow viscous liquid used in shampoos

2003 – Bacitracin

2002 – Thimerosal: antiseptic, antifungal used as a preservative in vaccines, ophthalmic and nasal products, tattoo ink

2001 – Gold

2000 – Disperse Blue

# Allergen of the Year

---

2020 – Isobornyl Acrylate

2019 – Parabens (Non) Allergen

2018 – Propylene Glycol

2017 – Alkyl Glucoside

2016 – Cobalt

2015 – Formaldehyde

2014 – Benzophenone

2013 – Methylisothiazolinone

2012 – Acrylate

2011 – Dimethyl fumarate is the chemical associated with 'poisoned chairs' and 'toxic sandals'.

2010 – Neomycin

2009 – Mixed dialkyl Thiourea = Neoprene rubber is a common source.

2008 – Nickel